

Protective Evaluation of Feed Fortified with *Alstonia Boonei* and *Mitracarpus Scaber* in African Catfish Exposed to *Aeromonas Hydrophila*: Clinicopathology and Immunohistochemistry

Abdullateef Ajadi^{1,2,*} , Theophilus Aghogho Jarikre² , Afusat Jagun Jibril² , Benjamin Emikpe² 

¹University of Ilorin, Faculty of Veterinary Medicine, Department of Veterinary Pathology, Ilorin/ Kwara, Nigeria

²University of Ibadan, Faculty of Veterinary Medicine, Department of Veterinary Pathology, Ibadan/ Oyo, Nigeria

How to cite

Ajadi, A.A., Jarikre T.A., Jubril J.A., Emikpe, B.O. (2023) Protective Evaluation of Feed Fortified with *Alstonia Boonei* and *Mitracarpus Scaber* in African Catfish Exposed to *Aeromonas Hydrophila*: Clinicopathology and Immunohistochemistry. *Aquaculture Studies*, 23(5), AQUAST1007. <http://doi.org/10.4194/AQUAST1007>

Article History

Received 13 Juner 2022

Accepted 13 November 2022

First Online 25 November 2022

Corresponding Author

Tel.: +2349061959556

E-mail: ajadi.aa@unilorin.edu.ng

Keywords

Dietary plants

Protection

Infection

Histopathology

Immunopathology

Abstract

The present study was carried out to determine the protective effects of two dietary plants and the associated pathology in African catfish exposed to *A. hydrophila*. Four hundred and twenty fish with average weight of 20.53 ± 0.15 g were distributed equally (in triplicates) into seven experimental groups (six treatment groups and a control group) with 20 juvenile African catfish in each aquarium. Fish were fed for 84 days with control and six other experimental diets containing different percentages of *Alstonia boonei* (0.5%, 1.0% and 1.5%) and *Mitracarpus scaber* (0.5%, 1.0% and 1.5%) of the basal diets. At the end of 12th week, the fish were challenged with *A. hydrophila* and clinical signs and mortality rate were observed for fourteen days, post challenge. Blood and tissue samples were collected for analysis. All the groups fed with plant supplemented feed had 100% survival rate except *A. boonei* (0.5%) with 85% and control had 70% survival rate. The dietary plants also improved the haematological parameters and reduced the histopathological lesions associated with *A. hydrophila* exposure, compared to the control. These findings have demonstrated the protective potentials of *A. boonei* and *M. scaber* inculcated in feed against *A. hydrophila* infection in African catfish.

Introduction

African catfish (*Clarias gariepinus*) is one of the most important species of aquaculture globally, due to its ease of cultivation and contribution to the economic growth of a nation (Dauda *et al.*, 2018). The intensification in the culture of this species and others has come with attendant challenges, chiefly is diseases outbreak, especially the ones caused by bacteria (Ajadi *et al.*, 2018). The aquaculture industry has come a long way in dealing with primary and/or secondary outbreak of bacterial diseases, which has subsequently resulted to humongous economic loss in both fresh and salt water fish farming due to decreased growth rate, increased mortality rate and expenses incurred for prophylactic and chemotherapeutic interventions

(Junior, 2021). Practically, African catfish (*C. gariepinus*) is often found in any freshwater environment and the condition of this environment enables *Aeromonas hydrophila*, the causative agent of motile aeromonas septicemia to thrive comfortably.

Of all the pathogens present in freshwater environment, 66.66% of fish bacterial diseases are caused by aeromonads group, especially *A. hydrophila* which is an important opportunistic fish pathogen in aquaculture system (Pattanayak *et al.*, 2020). Fish that exhibit bacterial haemorrhagic septicemias and infectious ulcerations are customarily associated with Motile aeromonads, which may be regarded as a complex of disease organisms in the past (Hossain & Heo, 2021). The clinical signs and symptoms of *A. hydrophila* infection include haemorrhagic septicemia,

abdominal distention, ulceration exophthalmia, anaemia, haemorrhages and high mortality (Chen *et al.*, 2020). In various aquaculture systems, several approaches including water chlorination, vaccination and use of antibiotics (both prophylaxis and chemotherapy) have been adopted to control the menace of *Aeromonas* infection. Meanwhile, improper and indiscriminate use of antibiotics has resulted in drug residue and emergence of multidrug-resistant strains of *A. hydrophila* (Muhammad *et al.*, 2020). The incessant use of antibiotics has brought about increased antimicrobial resistance with potential hazard on the aquatic ecosystem and humans. The rise in the antimicrobial resistant pathogens has also contributed to the rise in the rate of treatment failure and put the sustainability of aquatic animal production in jeopardy (Schar *et al.*, 2020). Recently, the use of antibiotics in aquaculture has been reduced, this may not be unconnected to the banning of these antimicrobial agents as growth promoters in several countries, thus, the need for better alternatives.

Plants and other phytogenic agents have been found among other better alternatives as fish growth promoters and to enhance virile immunity and protection against infectious diseases (Abdel-latif *et al.*, 2020). *Alstonia boonei* and *Mitracarpus scaber* are essential natural agents that have been reported to contain antimicrobial properties against myriads of infections (Owolabi *et al.*, 2013; Ogueke *et al.*, 2014; Ajadi *et al.*, 2021).

A. boonei has been widely used in the terrestrial animals for the treatment of various diseases due to the presence of bioactive components in all parts of the plant. Studies have shown that the plant has anti-inflammatory, anti-venom, anti-poison and antimicrobial properties and a potent compound in the treatment of ulcers which is commonly found in *aeromonas* infection (Akinmoladun *et al.*, 2007; Ogueke *et al.*, 2014; Ikechukwu *et al.*, 2021). In the same vein, *M. scaber* also contains bioactive ingredients that are used as therapeutic agents and feed additives. The plant has been reported to contain bactericidal and fungicidal properties which are employed in the treatment of various skin infections including wounds and ulcerations (Kwembe *et al.*, 2020; Ekalu, 2021; Nwofor *et al.*, 2021). The benefits of these two plants have not been extensively maximised in aquaculture. Earlier study revealed their growth promoting effect (Ajadi *et al.*, 2022). The objective of this study is to evaluate the protective effect and the associated pathology of feed fortified with *Alstonia boonei* and *Mitracarpus scaber* in African Catfish exposed to *Aeromonas hydrophila*.

Materials and Methods

Sources and Identification of Plants

Leaves of *A. boonei* and *M. scaber* were collected from areas of Ilorin International Airport and the

premises of Lagos State University staff quarters, Nigeria respectively. They were identified and authenticated at the Department of Plant Biology, University of Ilorin. Voucher specimens were deposited and voucher numbers were issued as UILH/001/196 and UILH/002/558 respectively.

Preparation of Plants

The leaves were thoroughly washed with clean water and air dried for fourteen days at room temperature after which they were pulverized into powdery forms according to Ogueke *et al.* (2014). The phytochemical and proximate analyses of these plants have been done in our previous studies (Ajadi *et al.*, 2021; Ajadi *et al.*, 2022).

Diet Preparation with Plants

Semi-purified diets based on casein were prepared and the compositions of all experimental diets were similar except for varieties of plant supplement. Diets were designed to meet the dietary requirements of African catfish. According to von Danwitz & Schulz (2020), with little modification, the feed was divided into seven groups. The percentages (0.5%, 1% and 1.5%) of each of the plant leaves were added to each of the experimental feed to make a total of 100% per treatment according to modified method of Adeniyi *et al.*, (2018). The control feed was without any plant additives. The feeds were thoroughly grinded, well mixed and eventually pelletized by addition of water and a binder (starch). The formed pastes were extruded through a manual mincing machine (with a 2mm die), optimally dried and stored in plastic bags @ 4°C until ready for use.

Experimental Design

Four hundred and twenty healthy *Clarias gariepinus* (African catfish) juveniles averagely weighing 20.53 ± 0.15 g were procured from a standard fish farm (Teejay feeds and fisheries Nig. Ltd) in Ilorin, Nigeria and were acclimatized for two weeks where they were fed with commercial diet (42% crude protein). The fish were randomly distributed equally (in triplicates) into seven experimental groups (six treatment groups and a control group). Each group contained 20 juvenile African catfish (*Clarias gariepinus*) in each circular plastic aquarium (50cm x 34cm x 27cm) of 40 litres capacity of water, totalling twenty-one (21) plastic aquaria in all. The tanks were well aerated and water quality parameters such as pH, temperature (°C) and dissolved oxygen (DO) and were measured weekly and maintained at 7.13 ± 0.02 , 26.98 ± 0.03 °C and 5.17 ± 0.01 ppm respectively. Dissolved oxygen and temperature were measured in-site using a portable oxygen meter (Jenway, London, UK), while pH meter (Digital Mini-pH Meter, USA) was used for the measurement of pH and temperature with

mercury thermometer. The fish were fed 4% of the total biomass twice daily (morning and evening) for the period of twelve weeks as described by El-gawad *et al.* (2020) with slight modification.

Bacterial Challenge

A. hydrophila (MT409620.1) obtained from a diseased African catfish and identified at International Institute of Tropical Agriculture (IITA) was used for the experimental infection as earlier described by (Ajadi *et al.*, 2021). Stock cultures were maintained at -80°C in a suspension of TSB with 15% glycerol. The challenge test was carried out with the *A. hydrophila* cultured in TSB (Difco Laboratories, Franklin Lakes, NJ, USA) from the stock at 25°C for 24 hours. The bacteria suspension was adjusted to an optical density of 0.5 at 540 nm corresponding to approximately 1.3×10^9 CFU/ml. At the end of 12 weeks of feeding, fifteen fish (five from each replicate) were randomly sampled. The challenge was done by immersion of fish into 5L of water + 1L of *A. hydrophila* broth for one hour before being transferred into their previous tank as described by (Adeshina *et al.*, 2021) with little modification. Clinical signs and mortality rate were observed for 14 days, post challenge. The mortality (%) was calculated as number of dead fish/total number of fish in the group x 100.

Blood Collection

Before sampling, fish were fasted for 24 h in order to obtain metabolite-free blood samples. Blood was collected from five fish (anaesthetised with 150 mg/l MS222 Argent Laboratories, Washington) from each group from the caudal vein using 23G needle with 2ml hypodermic syringe (Adeshina *et al.*, 2021). The blood samples for haematological analysis were collected into lithium heparinized tube for complete blood count and non-heparinized tube for serum chemistry and oxidative stress analyses after 14 days of bacterial challenge. The blood samples were put on ice and taken to the laboratory for the analyses.

Haematology

The white blood cell (WBC) and red blood cell (RBC) counts were determined by haemocytometry using an improved Neubauer haemocytometer. PCV was measured using the standard microhaematocrit method. Haemoglobin concentration (Hb) was determined by the cyanmethaemoglobin spectrophotometry method (Blaxhall & Daisley, 1973). The differential leukocyte counts were obtained from May-Grunwald-Giemsa stained blood smears (Sepperumal & Saminathan, 2013). The erythrocyte indices including mean corpuscular haemoglobin (MCH), mean corpuscular haemoglobin concentration (MCHC) and mean corpuscular volume (MCV) were calculated as $MCH = (Hb \times 10)/RBC$ in pictogram, $MCHC = (Hb \times$

$100)/PCV$ in g/dl and $MCV = (PCV \times 10)/RBC$ in femtolitre (Adamu and Solomon, 2015). Heterophil lymphocyte ratio (HLR) is a value obtained by the division of the absolute value of heterophils by that of the lymphocytes while PLR is the value obtained by dividing the value of the platelet count by the absolute value of the lymphocyte.

$$HLR = \frac{\text{Absolute peripheral blood cell count of heterophil}}{\text{Lymphocyte}}$$

$$PLR = \frac{\text{Platelet count}}{\text{Lymphocyte}}$$

Biochemical Analysis

The blood samples for serum biochemical tests were allowed to clot for 30 minutes at room temperature and then centrifuged at 3000 rpm for 15 minutes; sera were carefully decanted into labelled vials and stored at -20°C until analyzed. The serum samples were used in measuring the concentrations of total protein, albumin, globulin, creatinine (Cr), blood urea nitrogen (BUN) and cholesterol as well as the activities of alanine aminotransferase (ALT), aspartate aminotransferase (AST) and alkaline phosphatase (ALP) using commercial test kits (Agappe, India), using a digital ultraviolet spectrophotometer following the description of the manufacturer.

Oxidative Stress Markers Analysis

At 3000 rpm for 10 minutes, serum samples for biochemical analyses were centrifuged using Hawsley bench centrifuge (P specra, Centromix no 231254 CD7000549, Spain). The samples properly were stored at -20°C until used for the analyses. The serum levels of superoxide dismutase (SOD), Glutathione peroxidase (GPx), malonaldehyde (MDA), Myeloperoxidase (MPO), Glutathione-S-transferase (GST) and catalase were measured using commercially available standard kits (Nanjing Jiancheng Bioengineering Co. Ltd., China), following the description of the manufacturer.

Histopathology

Five fishes were sampled randomly from each group at 14 days post-challenge with *A. hydrophila* for histopathological analysis. The fish were sacrificed by pitting technique where tissues including liver, gills and kidney were harvested and preserved in Davidson's AFA fixative for 24 h and later transferred to 70% ethyl alcohol (Ajadi *et al.*, 2019). Following 24 hours after fixation, the standard histological procedure described by Bell and Lightner (1988) was followed. The tissues were trimmed and dehydrated in ascending grades (70–100%) of ethanol, cleared in xylene, followed by embedding in paraffin wax and the tissue sections of tissue sections of 5 µm thickness were cut using

microtome (YD 335). The sections were then stained with haematoxylin and eosin (H&E) and examined with a light microscope (Olympus CH). Histopathological alterations in each organ were scored (semi quantitatively) as none (0), mild (1), moderate (2) or severe (3).

Immunohistochemistry

The method of Ajadi *et al.* (2019) was followed with little modifications. The Davidson solution-fixed tissue samples (liver and kidney) of all the groups were embedded in paraffin and serial 5 µm thick sections were cut from the paraffin embedded tissue blocks onto charged glass slides. The slides were dried for 15 min at 56 °C, dewaxed in xylene for 5 min and rehydrated through a graded concentration of alcohol. The slides were rinsed with running tap water for 30 s and placed in PBS for 10 min. Heat-mediated antigen retrieval with citrate buffer solution was done to enhance immunoreactivity of the tissue with microwave oven where it was incubated for 10 min at 50 W and rinsed with PBS. Freshly prepared 3% hydrogen peroxide was used to block the activity of endogenous peroxidase for 5 min at room temperature and gently washed with PBS for 2 min. Tissue sections were blocked with blocking buffer (1% normal serum [Bovine serum albumin] in PBST), then sections were incubated in rabbit anti-*A. hydrophila* antibody at a dilution of 1:50 (antibody to 5% BSA in PBS ratio) for 1 h at 37 °C in an incubator with Rabbit anti *A. hydrophila* with the dilution of 1:50 for at least 1 h at 37°C in an incubator. The sections were rinsed and washed in PBS for 5 min, and were incubated again with secondary antibody (goat anti-Rabbit IgG HRP, ab6721) with the dilution of 1:100. The slides were rinsed and washed with PBST for 5 minutes upon which DAB was applied (1 ml diluents to a drop DAB (3,3'-diaminobenzidine) (DAKO, USA) for colour change. The slides were immediately rinsed with distilled water as soon as the sections turned brown. The slides were counter stained using Mayer's haematoxylin solution for background colour. All slides were analysed and captured using image analyser NIS-Elements D 3.2 (Nikon, Japan). The images were quantified for staining intensity with the use of open Fiji (Image J) software (Ferreira and Rasband 2012).

Statistical Analysis

The data obtained were input in Microsoft excel sheet and analysed with one-way analysis of variance (ANOVA) using IBM statistical package (SPSS version 20) to determine differences among the treatments and control in all parameters. Individual means were separated with Duncan multiple range test. All data were recorded as means ± SE, and were presented as significant at $P < 0.05$ according to Dytham (2011).

Results

Survival Rate and Clinical Signs

The survival rate of the groups after 14 days of bacterial challenge is shown in Figure 1. All the groups fed with plant supplements except A1 (*A. boonei* 0.5%) had 100% survival rate. Generally, all the groups supplemented with the plant additives had noticeably higher survival rate (85 -100%) compared to the non-supplemented group (70%). Figures 2 (A & B) showed the gross lesions such as skin ulcerations, haemorrhages and fin rot in some of the surviving fish especially in the control group while Figure 2C showed apparently lesion free fish belonging to one of the treatment groups.

Haematological Indices

Dietary *A. boonei* and *M. scaber* at different gradients showed significant difference ($P < 0.05$) in the haematological parameters between the treatment groups and the control after 14 days of *A. hydrophila* challenge (Table 1). The values of RBC, Hb, PCV were the lowest in the control group but the highest in the *M. scaber* (0.5%) group. The values of WBC were significantly higher in the control and *M. scaber* (1.5%) groups than the other treatments groups. The HLR and PLR were significantly higher in the control than the diet-supplemented groups.

Serum Analyses and Oxidative Stress Biomarkers

Biochemical parameters are shown in Table 2. The values of total protein, albumin and globulin were significantly higher in some of the treatment groups than the control. The *M. scaber* (0.5%) had the highest total protein and globulin ($P < 0.05$) while the group *A. boonei* (0.5%) had the highest albumin value ($P < 0.05$) with the control group having the lowest. The concentration of BUN and creatinine was also significantly higher ($P < 0.05$) in the plant supplemented feed group than the control. There was no significant difference ($P > 0.05$) in the value of ALT between and some of the treatment groups but the *M. scaber* (1.5%) group had the significant lowest values compared to the control and other treatment groups. AST showed significant difference ($P < 0.05$) between the control and treatment groups while ALP did not show significant difference between the control and treatment groups except the group *M. scaber* (0.5%) that showed significantly ($P < 0.05$) lower value compared to the control. Table 3 showed that there was significant increase ($P < 0.05$) in the activity of superoxide dismutase SOD glutathione peroxidase (GPX) in the treatment groups more than the control. The value of MDA in the control group was insignificantly higher than that of *A. boonei* (0.5%, 1.0% and 1.5%) and *M. scaber* (0.5%) but significantly higher than *M. scaber* (1.0% and 1.5%). There was no significant difference in the activity of

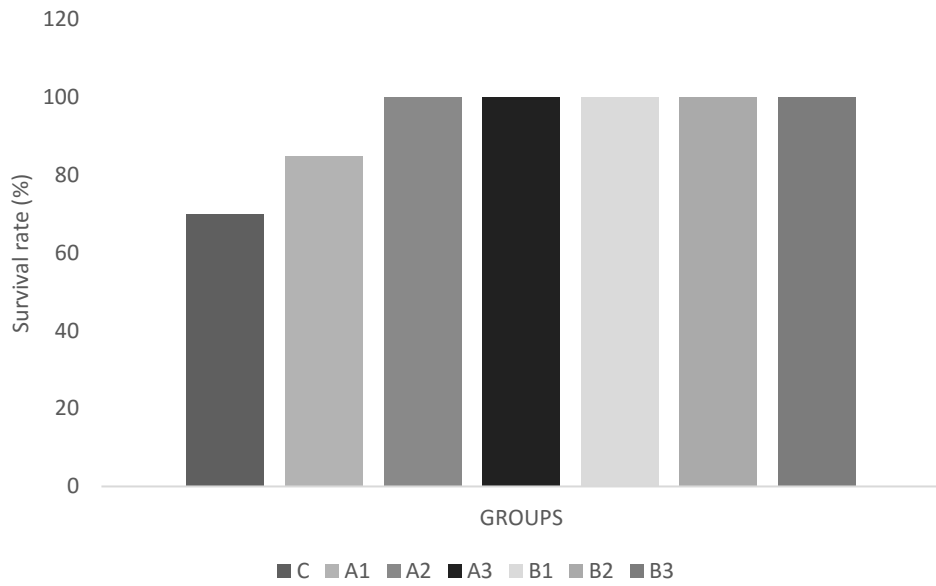


Figure 1. Survival rate of the groups 14 days post bacterial challenge.

Keys: C: control group; A1: *A. hydrophila* (0.5%); A2: *A. hydrophila* (1.0%); A3: *A. hydrophila* (1.5%); B1: *M. scaber* (0.5%); B2: *M. scaber* (1.0%); B3: *M. scaber* (1.5%)



Figure 2. A: Fish from the control group showing focal area of large ulceration (arrow) with some ecchymotic haemorrhages at the rostral region 5 days after *A. hydrophila* challenge. B: Fish from the control group showing fin rot (arrow), skin discoloration and multifocal areas of ulceration at the caudal region of ulceration with some ecchymotic haemorrhages at the rostral region 7 days after *A. hydrophila* challenge. C: Fish from *M. scaber* (0.5%) group showing apparently no skin lesions or ulcerations 7 days after *A. hydrophila* challenge.

catalase and MPO between the control and the treatment groups.

Histopathology and Immunohistochemistry (IHC)

Samples were taken from kidney, liver and gill of different groups of fish 14 days after *A. hydrophila* challenge. The respective histopathology of the liver, kidney and gill of different groups are shown in Figures 3, 4 and 5. The liver of the fish fed with control diet revealed dilation of the sinusoid, fatty degeneration of the hepatocyte, mild congestion and leucocytic

infiltration of the sinusoid (Figure 3A). In the groups fed with graded *A. boonei* (0.5%, 1.0% and 1.5%), the liver showed varying lesions including atrophy of the hepatic plates, mild to moderate hepatocellular degeneration, mild congestion of the central venules and no observable lesions (Figures 3 B – D). In the groups fed with graded *M. scaber* (0.5%, 1.0% and 1.5%), the histopathological lesions of the liver include mild congestion of the sinusoids and central venules with many fish showing no observable lesions (Figures 3 E-G). Tubular epithelial degeneration, necrosis and inflammatory cells infiltration are evident in the kidney

Table 1. Haematological parameters of African catfish fed with and without *A. boonei* and *M. scaber* and challenged with *A. hydrophila*

Parameters	Control	<i>A. boonei</i> (0.5%)	<i>A. boonei</i> (1.0%)	<i>A. boonei</i> (1.5%)	<i>M. scaber</i> (0.5%)	<i>M. scaber</i> (1.0%)	<i>M. scaber</i> (1.5%)
RBC (×10 ⁶)	2.55±0.24 ^a	4.88±0.15 ^{bc}	5.21±0.73 ^{bc}	4.02±0.41 ^{abc}	5.77±0.07 ^c	3.64±0.17 ^{ab}	4.69±1.09 ^{bc}
HGB (g/dl)	5.33±0.53 ^a	9.77±0.23 ^{bc}	10.30±1.50 ^{bc}	8.80±1.15 ^{abc}	11.30±0.06 ^c	6.90±0.50 ^{ab}	9.17±2.06 ^{bc}
PCV (%)	18.33±1.67 ^a	29.67±0.67 ^{bc}	32.33±4.33 ^{bc}	26.00±3.06 ^{abc}	34.67±0.33 ^c	21.33±1.33 ^{ab}	29.67±6.84 ^{bc}
MCV (fl)	60.33±0.33 ^a	60.67±0.67 ^a	61.00±0.00 ^a	61.00±0.58 ^a	60.00±0.00 ^a	61.67±1.67 ^a	61.00±0.58 ^a
MCH (pg)	19.97±0.33 ^a	19.80±0.20 ^a	20.17±0.03 ^a	18.83±0.91 ^a	19.70±0.21 ^a	20.07±0.46 ^a	20.17±0.15 ^a
MCHC (g/dl)	32.33±0.28 ^a	32.17±0.67 ^a	32.80±0.12 ^a	31.07±1.74 ^a	32.47±0.37 ^a	32.10±0.10 ^a	32.40±0.21 ^a
WBC (×10 ³)	12.00±0.00 ^b	8.71±0.75 ^a	7.85±1.70 ^a	7.45±0.22 ^a	8.05±1.29 ^a	6.99±0.46 ^a	12.16±0.06 ^b
HET (×10 ³)	6.94±0.42 ^c	3.81±0.47 ^{ab}	3.64±1.05 ^a	2.89±0.01 ^a	3.49±0.42 ^a	2.80±0.44 ^a	5.33±0.07 ^b
LYM (×10 ³)	4.88±0.49 ^a	4.67±0.32 ^a	3.99±0.64 ^a	4.20±0.15 ^a	4.49±0.86 ^a	3.96±0.13 ^a	6.57±0.05 ^b
EOS (×10 ³)	0.00±0.00 ^a	0.09±0.01 ^a	0.03±0.03 ^a	0.00±0.00 ^a	0.03±0.03 ^a	0.06±0.03 ^a	0.00±0.00 ^a
MONO (×10 ³)	0.18±0.09 ^a	0.14±0.04 ^a	0.25±0.04 ^a	0.19±0.03 ^a	0.09±0.01 ^a	0.17±0.11 ^a	0.26±0.06 ^a
PLT (×10 ³)	387.00±0.7.02 ^c	292.00±6.35 ^b	208.00±8.72 ^a	217.00±31.79 ^{ab}	230.67±51.02 ^{ab}	287.00±13.65 ^b	391.00±9.64 ^c
HLR	1.46±0.23 ^b	0.81±0.05 ^a	0.87±0.13 ^a	0.69±0.02 ^a	0.81±0.11 ^a	0.70±0.09 ^a	0.81±0.02 ^a
PLR	81.09±9.26 ^c	63.34±5.22 ^{abc}	54.05±6.22 ^{ab}	51.38±6.16 ^a	50.79±1.86 ^a	72.66±5.80 ^{bc}	59.49±1.63 ^{ab}

*Different letters as superscripts across the rows indicate significant differences (P<0.05). RBC (red blood cell); HGB (haemoglobin); PCV (packed cell volume); MCV (mean corpuscular volume); MCH (mean corpuscular haemoglobin); MCHC (mean corpuscular haemoglobin concentration); WBC (white blood cell); HET (heterophil); LYM (lymphocyte); EOS (eosinophil); MON (monocyte); PLT (platelet); HLR (heterophil lymphocyte ratio); PLR (platelet lymphocyte ratio).

Table 2. Serum biochemical analysis of African catfish fed with and without *A. boonei* and *M. scaber* and challenged with *A. hydrophila*

Parameters	Control	<i>A. boonei</i> (0.5%)	<i>A. boonei</i> (1.0%)	<i>A. boonei</i> (1.5%)	<i>M. scaber</i> (0.5%)	<i>M. scaber</i> (1.0%)	<i>M. scaber</i> (1.5%)
ALP (U/L)	49.46±0.64 ^b	49.18±0.77 ^b	49.81±0.42 ^b	45.85±2.31 ^{ab}	44.68±0.47 ^a	47.16±0.45 ^{ab}	47.86±2.46 ^{ab}
AST (U/L)	102.07±3.20 ^c	81.05±8.01 ^b	93.01±1.36 ^{bc}	77.86±11.99 ^b	81.07±3.69 ^b	77.50±2.62 ^b	58.78±2.20 ^a
ALT (U/L)	96.75±5.46 ^b	80.39±9.39 ^{ab}	96.66±0.10 ^b	88.95±10.04 ^b	94.63±4.84 ^b	82.78±12.90 ^{ab}	61.00±3.03 ^a
PROTEIN(g/dL)	10.99±2.45 ^a	13.69±0.03 ^{ab}	14.67±1.35 ^{ab}	13.75±2.36 ^{ab}	16.01±0.23 ^b	11.61±0.05 ^{ab}	11.49±0.01 ^{ab}
ALBUMIN(g/dL)	3.01±0.94 ^a	5.44±0.04 ^b	4.48±0.09 ^{ab}	4.04±1.14 ^{ab}	3.53±0.92 ^{ab}	3.63±0.35 ^{ab}	3.51±0.04 ^{ab}
GLOBULIN(g/dL)	7.98±1.52 ^a	8.24±0.01 ^a	10.18±1.43 ^{ab}	9.71±1.22 ^{ab}	12.47±0.69 ^b	7.98±0.39 ^a	7.98±0.18 ^a
AGR	0.36±0.04 ^a	0.66±0.01 ^b	0.46±0.06 ^a	0.39±0.08 ^a	0.29±0.09 ^a	0.46±0.07 ^a	0.39±0.01 ^a
CREAT (mg/dL)	48.00±10.00 ^{ab}	78.00±10.00 ^c	81.33±13.33 ^c	71.33±13.33 ^b	54.67±3.33 ^{ab}	68.00±10.00 ^{bc}	48.00±10.00 ^{ab}
BUN (mg/dL)	7.05±0.28 ^a	11.78±0.32 ^c	10.94±0.34 ^{bc}	11.21±2.19 ^{bc}	9.76±1.33 ^{abc}	7.99±0.20 ^{ab}	6.65±0.02 ^a
CHOL (mg/dL)	165.28±25.34 ^a	183.18±5.21 ^{ab}	226.59±2.79 ^b	177.89±34.89 ^{ab}	198.32±7.32 ^{ab}	154.83±1.65 ^a	143.51±3.32 ^a

*Different letters as superscripts across the rows indicate significant differences (P<0.05). ALP (alkaline phosphatase); AST (aspartate aminotransferase); ALT (alanine aminotransferase); ALB (albumin); GLOB (globulin); AGR (albumin globulin ratio); CREAT (creatinine); BUN (blood urea nitrogen); CHOL (cholesterol).

Table 3. Oxidative stress markers of African catfish fed with and without *A. boonei* and *M. scaber* and challenged with *A. hydrophila*

Parameters	Control	<i>A. boonei</i> (0.5%)	<i>A. boonei</i> (1.0%)	<i>A. boonei</i> (1.5%)	<i>M. scaber</i> (0.5%)	<i>M. scaber</i> (1.0%)	<i>M. scaber</i> (1.5%)
SOD (IU/L)	0.50±0.16 ^a	0.71±0.12 ^a	1.35±0.07 ^b	2.12±0.16 ^c	1.64±0.07 ^b	2.15±0.12 ^c	2.17±0.12 ^c
GST (IU/L)	0.06±0.00 ^a	0.07±0.01 ^a	0.17±0.02 ^b	0.09±0.06 ^{ab}	0.10±0.00 ^{ab}	0.05±0.02 ^a	0.05±0.01 ^a
MPO (IU/L)	815.66±153.48 ^{ab}	1468.14±682.44 ^a	986.95±323.21 ^a	1375.57±138.60 ^a	1125.42±12.54 ^a	2312.71±1193.94 ^a	1560.84±608.63 ^a
MDA (IU/L)	18.86±0.97 ^b	14.84±5.16 ^{ab}	13.78±0.14 ^{ab}	11.07±3.29 ^{ab}	13.72±0.03 ^{ab}	8.72±0.93 ^a	6.80±0.73 ^a
GPX (IU/L)	109.19±14.10 ^a	124.05±39.58 ^a	265.41±27.02 ^b	202.64±5.20 ^b	247.46±27.66 ^b	243.60±8.42 ^b	238.13±5.25 ^b
CAT (IU/L)	9.77±1.73 ^a	14.02±1.21 ^a	15.90±2.28 ^a	12.92±3.07 ^a	14.43±1.08 ^a	12.37±1.86 ^a	8.82±0.26 ^a

*Different letters as superscripts across the rows indicate significant differences (P<0.05)

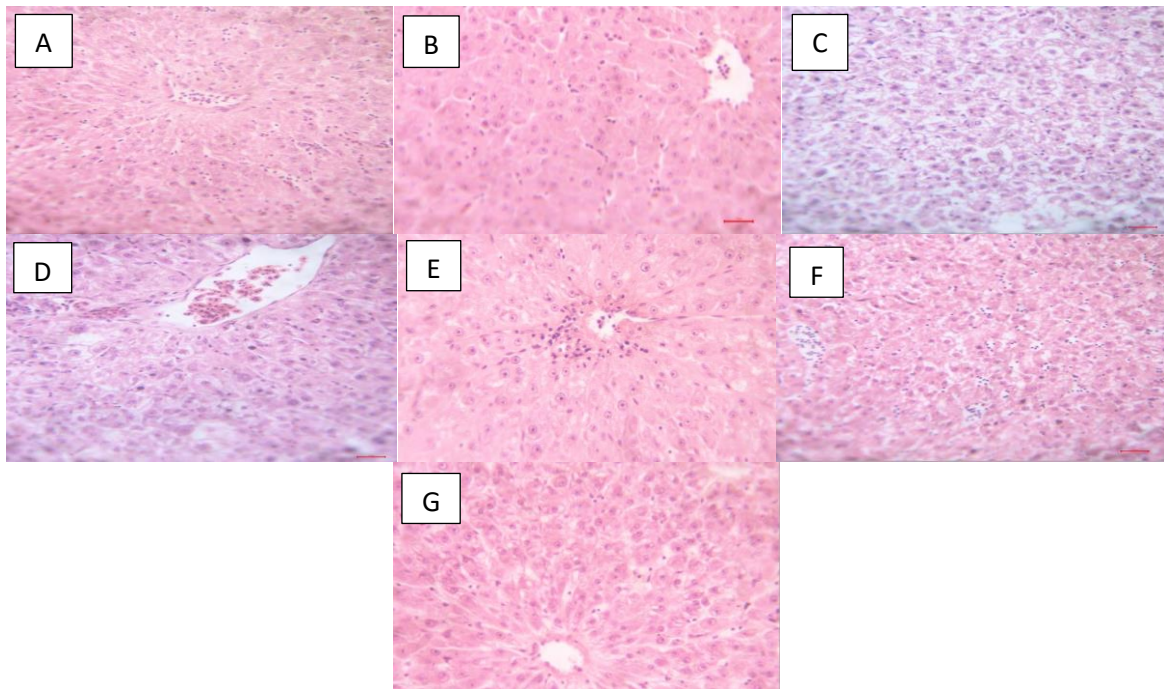


Figure 3. photomicrograph of African catfish liver 14 days after challenged with *A. hydrophila* in different groups fed with and without *A. boonei* and *M. scaber* for 12 weeks. (A) control group without plant additives showing moderate atrophy of centrilobular hepatic plates (blue asterisk), congestion and accentuation of sinusoids (red asterisk). HE x400 (B) *A. boonei* (0.5%) showed mild congestion of central venules (blue asterisk). HE x400 (C) *A. boonei* (1.0%) atrophy of hepatic plates and moderate hepatocellular degeneration (blue asterisk). HE x400 (D) *A. boonei* (1.5%) mild congestion of central venules (blue asterisk). HE x400 (E) *M. scaber* (0.5%) mild congestion of central venules and sinusoids (blue asterisk). HE x400 (F) *M. scaber* (1.0%) mild congestion of central venules and sinusoids (blue asterisks). HE x400 (G) *M. scaber* (1.5%) no observable lesion. HE x400.

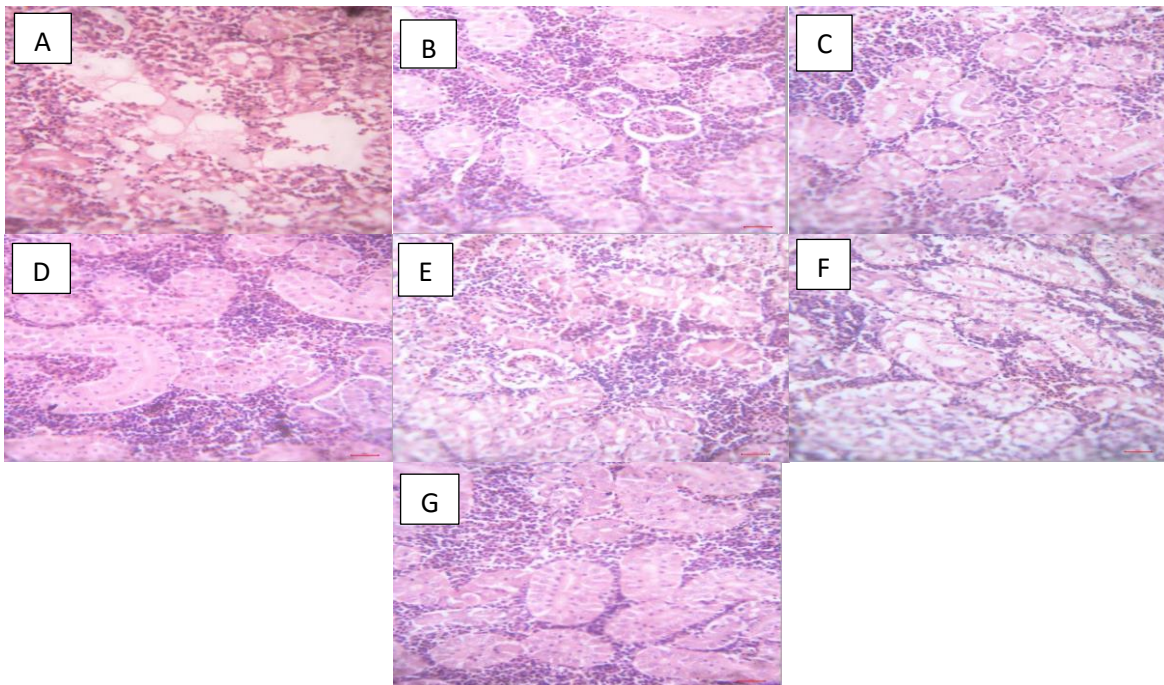


Figure 4. photomicrograph of African catfish kidney 14 days after challenged with *A. hydrophila* in different groups fed with and without *A. boonei* and *M. scaber* for 12 weeks. (A) control group without plant additives showing tubular epithelial degeneration (blue asterisk), necrosis (red asterisk) and inflammation (yellow asterisk). HE x400 (B) *A. boonei* (0.5%) showed patchy tubular epithelial degeneration (blue asterisk). HE x400 (C) *A. boonei* (1.0%) showed no observable lesion. HE x400 (D) *A. boonei* (1.5%) showed no observable lesion. HE x400 (E) *M. scaber* (0.5%) showed patchy tubular epithelial degeneration (blue asterisk). HE x400 (F) *M. scaber* (1.0%) showed patchy tubular epithelial degeneration (blue asterisk). HE x400 (G) *M. scaber* (1.5%) showed no observable lesion. HE x400.

of the control group (Figure 4A). The kidney of the fish fed with graded *A. boonei* (0.5%, 1.0% and 1.5%) and *M. scaber* (0.5%, 1.0% and 1.5%) appeared to have no observable lesions while few had mild tubular epithelial degeneration (Figures 4 B – G). The gill of the fish fed with the control diet was characterized with mild congestion of the blood vessel, inflammatory cells infiltration and degeneration and separation of secondary filaments (Figure 5A). The fish of the groups fed with both plant additives had their gills with no observable lesion that is apparent with some showing mild congestion of the blood vessel of the primary lamellae (Figures 5 B-G). Table 4 shows the extent of the microscopic lesions in the liver, kidney and gill of all the groups. Figures 6 and 7 are showing immunostaining of *A. hydrophila* antigens in kidney and liver of all fish groups with more immunoreactivity intensity in the group fed with control diet than the groups fed with plant additives.

Discussion

The menace of disease outbreak and subsequent use of all manners of antibiotics to prevent and control diseases had resulted into humongous economic loss and inefficient disease control. The adoption of phytogenic agents is sinequanone, because the natural compounds are biodegradable, eco-friendly, no resistance to pathogens and contain various bioactive ingredients which are responsible for their antimicrobial activities. Grossly, the observed result revealed that, African catfish infected with *A. hydrophila* showed clinical signs as ulcerative skin, haemorrhages on body surface and fin rot, ulcers with mortality up to 30% in the control group, these could be attributed to the pathogenic effect of the bacterial organism. Similar pathology and mortality rate were observed by Zhang *et al.* (2020). Albeit plethora of studies have been reported in the control of aeromonas infection in fish (Abdel-tawwab & El-araby, 2021; Moustafa *et al.*, 2020), the outbreak has not ceased to recurring and mortality is usually high. It was evident in this study that the plant additives (*A. boonei* and *M. scaber*) in different percentages enhanced the survival rate of the fish after challenged with *Aeromonas hydrophila*. This may not be unconnected with the antimicrobial properties of the plants. *A. boonei* (Ogueke *et al.*, 2014; Opoku & Osei, 2014) and *M. scaber* (Adeshina *et al.*, 2019, 2021; Ajadi *et al.*, 2021) have been reported to contain bioactive components such as such as flavonoids, alkaloids, phenols, saponins, tannins among other aromatic compounds that play important roles in defence mechanism against microbial organisms. This is evident in this study where the fish fed with *A. boonei* and *M. scaber* had higher survival rate than the control. The protection is irrespective of the percentage of the plant present in the feed except *A. boonei* (0.5%) with 85% survival rate against other groups with 100% survival rate. This finding is in agreement with Adeshina *et al.*

(2019) that reported the protective effect of *M. scaber* against *A. hydrophila* in common carp. There is dearth of information on the protective effect of dietary *A. boonei* in fish.

Haemato-biochemical indices are essential clinical tools employed to examine fish health status (Abdel-Tawwab & Hamed, 2020). One of the virulence factors characterized by *A. hydrophila* is the production of haemolysin which alters the haematological indices of the host it infects (Han *et al.*, 2020). Chen *et al.* (2020) also reported the apoptosis of RBC induced by *A. hydrophila* infection. It is evident in this study that the erythrocyte indices of groups of fish fed with feed supplemented with *A. boonei* and *M. scaber* improved the haematological parameters more than the control group after *A. hydrophila* challenge. This may be attributed to numerous phytoactive components present in the plants. Akinmoladun *et al.* (2007) reported that *A. boonei* contained numerous minerals and vitamins in which vitamin C and iron were more abundant in addition to other phytochemicals. These are essential ingredients for blood formation. *M. scaber* has also been reported to contain several bioactive components and essential oils that may also be associated with its medicinal properties (Ali *et al.*, 2021; Ekalu, 2021). The significant differences in the values of WBC which was higher in the control group than the treatment groups except *M. scaber* (1.5%) may be connected to the reaction of the fish to the bacterial challenge whereby the heterophils were mobilized against invading *A. hydrophila*. This is in agreement with Harikrishnan *et al.* (2003) that reported a significant increase in the values of WBC in common carps, 10 days after infected with *A. hydrophila* and the further increase, 30 days post infection. On the other hand, the reverse was the case in the groups treated with *Azadirachta indica*. Since haematological ratio is an important prognostic parameter for evaluation of health status in a diseased subject (Ulas *et al.*, 2015), the lower significant values of HLR and PLR in the treatment groups than the control indicates that the prognosis is better in the former than the latter.

The higher serum total proteins especially the globulins in the treatment group (*M. scaber* 0.5%) than the control in this study might be associated with improved immune response due to increased globulins. The increase in the values of creatinine and BUN in treatment groups more than the control in this present study is in concomitant with the finding of Adeshina *et al.* (2021) who reported significant increase in fish fed plants materials-extracts based diets than the control group. The liver enzymes did not reveal much significant differences between the treatment groups and control except for AST that was higher in the latter than the former. The *A. hydrophila* might cause moderate hepatocyte damages but the fish fed with plant supplements were not affected as much as the control. Oxidative stress markers provide valuable tools in evaluating the health status of fish. Important enzymes

such as SOD, GPx, GSH, MPO, MDA and CAT are important markers used in the evaluation of oxidative stress in fish (Chen *et al.*, 2020; Abdel-tawwab & El-araby, 2021). In this study, the dietary administration *A. boonei* and *M. scaber* to African catfish for 84 days and subsequent *A. hydrophila* challenged, increased the activities of SOD, GPx, GSH and MPO but reduced MPO when compared with the control. This could be attributed to antioxidant properties of the phenolic and other phytoactive compounds present in *A. boonei* (Obiagwu *et al.*, 2014; Opoku & Osei, 2014) and *M. scaber* (Ali *et al.*, 2021; Ekalu, 2021). These findings share similar observations with Adeshina *et al.* (2021) and Abdel-tawwab and El-Araby (2021) who reported elevated SOD, CAT and GPx, and reduction in the activities of MDA due to dietary plants in Nile tilapia challenged with *Gyrodactylus malalai* and *A. hydrophila*

respectively. The histological alterations of the liver observed in this study in the fish fed with control diet after *A. hydrophila* challenge include dilation of the sinusoid, fatty degeneration of the hepatocyte, mild congestion and leucocytic infiltration of the sinusoid. These similar findings were reported by Hal *et al.* (2020) who described the histological alterations of the liver of *A. hydrophila* group as vacuolar degeneration, hypoplasia of hepatocytes, dilatation in sinusoids and fibrosis. Histopathological findings on the kidney in the control group revealed tubular epithelial degeneration, necrosis and inflammatory cells infiltration. Similar observations were earlier reported by Hal *et al.*, (2020) that the kidney of Nile tilapia infected with *A. hydrophila* revealed interstitial mononuclear cell infiltration and tubular degeneration.

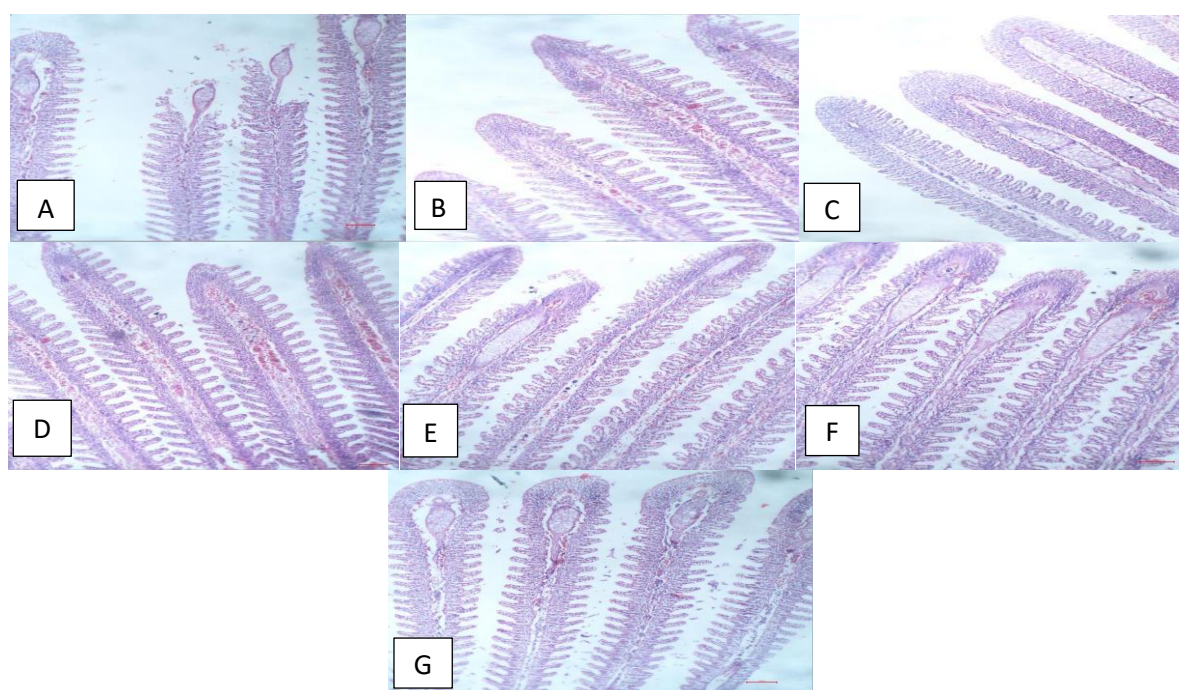


Figure 5. photomicrograph of African catfish gills 14 days after challenged with *A. hydrophila* in different groups fed with and without *A. boonei* and *M. scaber* for 12 weeks. (A) control group without plant additives showing mild congestion of the blood vessel (blue asterisk) and degeneration and separation of secondary lamellae (red asterisk). HE x100 (B) *A. boonei* (0.5%) showed moderate congestion of capillaries of the primary lamellae (blue asterisk). HE x100 (C) *A. boonei* (1.0%) showed moderate hyperplasia and fusion of secondary lamellae (red asterisk). HE x100 (D) *A. boonei* (1.5%) showed moderate congestion of capillaries (blue asterisk). HE x100 (E) *M. scaber* (0.5%) showed erosion of the secondary lamellae at the apical region of the primary lamellae (yellow asterisk). HE x100 (F) *M. scaber* (1.0%) showed no observable lesions. HE x100 (G) *M. scaber* (1.5%) showed no observable lesions. HE x100.

Table 4. Qualitative scoring of lesions from the microscopic examination of tissues from the groups of fish

Group	Liver	Kidney	Gills
Control	++	+++	+
<i>A. boonei</i> (0.5%)	+	+	+
<i>A. boonei</i> (1.0%)	++	-	+
<i>A. boonei</i> (1.5%)	+	-	+
<i>M. scaber</i> (0.5%)	+	+	+
<i>M. scaber</i> (1.0%)	+	+	-
<i>M. scaber</i> (1.5%)	-	-	-

Key: -: none; +: mild; ++: moderate; +++: severe

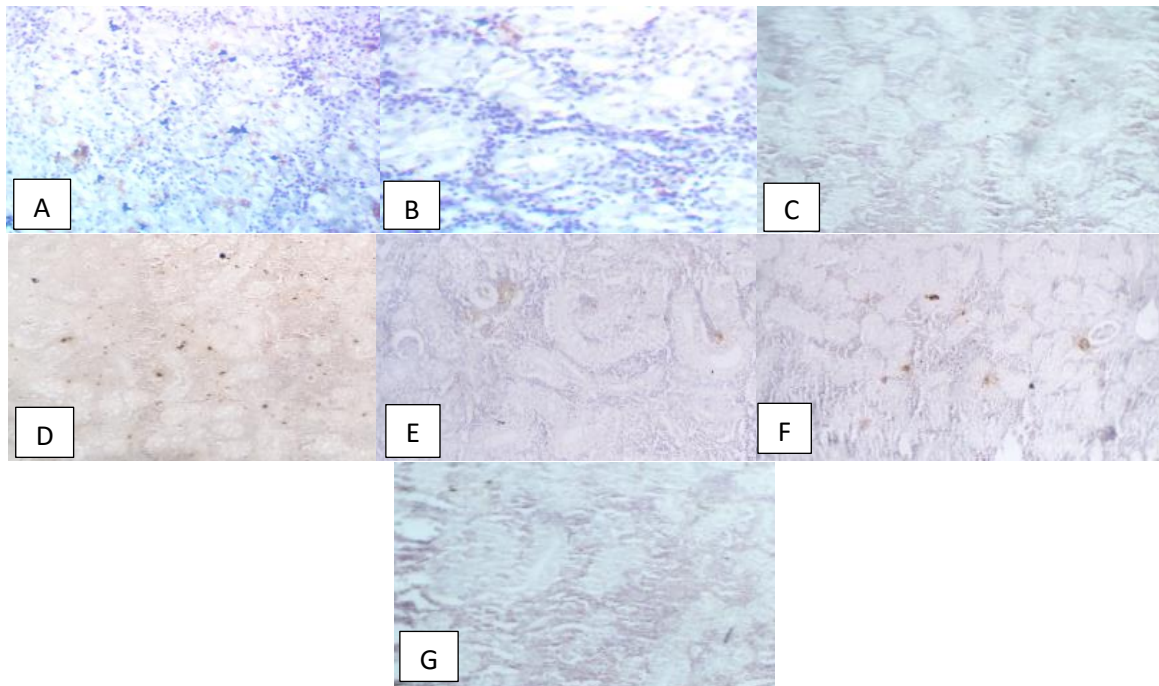


Figure 6. Photomicrograph of immunostaining of *A. hydrophila* antigens (asterisk) in the kidney 14 days after challenged with *A. hydrophila* in different groups fed with and without *A. boonei* and *M. scaber* for 12 weeks. (A) control group without plant additives showing moderate immunoreactivity. (B) *A. boonei* (0.5%), (C) *A. boonei* (1.0%), (D) *A. boonei* (1.5%), (E) *M. scaber* (0.5%), (F) *M. scaber* (1.0%) and (G) *M. scaber* (1.5%) groups showing mild immunoreactivity to polyclonal antibody. Haematoxylin counter stain, 400.

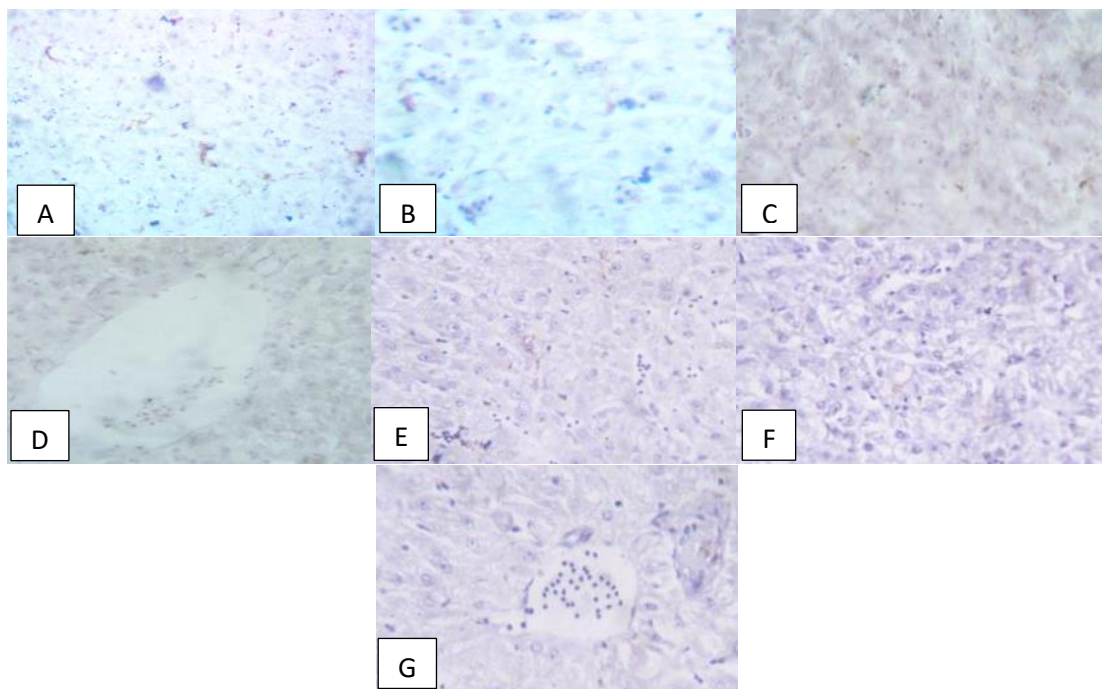


Figure 7. Photomicrograph of immunostaining of *A. hydrophila* antigens in the liver 14 days after challenged with *A. hydrophila* in different groups fed with and without *A. boonei* and *M. scaber* for 12 weeks. (A) control group without plant additives and (B) *A. boonei* (0.5%) showing moderate immunoreactivity (C) *A. boonei* (1.0%), (D) *A. boonei* (1.5%), (E) *M. scaber* (0.5%), (F) *M. scaber* (1.0%) and (G) *M. scaber* (1.5%) groups showing mild immunoreactivity to polyclonal antibody. Haematoxylin counter stain, 400.

Immunohistochemistry is an essential diagnostic and investigative tool that allows the identification of tissue components through antigen-antibody reaction (Ajadi *et al.*, 2019). This present study demonstrated that specific antigen of *A. hydrophila* could be identified in Davidson's fixative paraffin-embedded tissue samples of African catfish challenged with the putative organism using immunoperoxidase technique. This present finding is consistent with the report of Delghandi *et al.*, (2020) whose study made use of immunoperoxidase technique to detect the antigens of *Renibacterium salmoninarum* and *Mycobacterium* sp. in the tissues of wild brown trout. The immunoreactivity of *A. hydrophila* antigen to antibody occurred in the interstitial space of the kidney and in the sinusoids of the liver with more intensity in the control group than the treatment groups. The less intensity in the groups fed with plant supplemented feed is indicative of protective potentials of the dietary plants resulting in the reduced amount of the bacterium in the sampled tissues.

Conclusion

The findings of this study demonstrated the protective potentials of feed separately fortified with *A. boonei* and *M. scaber* against *Aeromonas* infection in African catfish. It is also evident that the dietary plants improved the haematological parameters and antioxidant enzymes of the fish as well as reduction of pathological lesions associated with *A. hydrophila* infection. However, the lowest percentage (0.5%) of each plant supplements is recommended as appropriate and further study on the toxicity effect of the long term administration of these plants is expedient.

Ethical Statement

All experiments were reviewed and carried out in conformity with the local and international standards of animal care and welfare, and of the Animal Care and Use Research Ethics Committee of University of Ibadan with the assigned number (UI-ACUREC/052-0521/26).

Funding Information

The authors declare that no funds, grants, or other support were received during the preparation of this manuscript

Author Contribution

First Author (A.A. Ajadi): Conceptualization, Methodology, Writing -original draft; Second Author (T.A. Jarikre): Formal Analysis; Writing -review and editing; Third Author (J.A. Jibril): Supervision; Writing -review and editing; Fourth Author (B.O. Emikpe): Conceptualization, Formal Analysis, Investigation, Methodology, Supervision; Writing -review and editing

Conflict of Interest

The author(s) declare that they have no known competing financial or non-financial, professional, or personal conflicts that could have appeared to influence the work reported in this paper.

Acknowledgements

The authors acknowledge Mr. Moshood Bolaji and Mr Adegboye Afolabi of the Department of Veterinary Pathology, University of Ilorin, Nigeria, for the haematological analysis and Tissue processing respectively. The authors also appreciate German-West African Centre (G-WAC) and Kwame Nkrumah University of Science and Technology (KNUST), Ghana for the support and providing some of the facilities used in the course of this research

References

- Abdel-latif, H.M.R., Abdel-tawwab, M., Khafaga, A.F., & Dawood, M.A.O. (2020). Dietary oregano essential oil improved antioxidative status, immune-related genes, and resistance of common carp (*Cyprinus carpio* L.) to *Aeromonas hydrophila* infection. *Fish and Shellfish Immunology*. <https://doi.org/10.1016/j.fsi.2020.05.056>
- Abdel-tawwab, M., & El-araby, D.A. (2021). Immune and antioxidative effects of dietary licorice (*Glycyrrhiza glabra* L) on performance of Nile tilapia, *Oreochromis niloticus* (L.) and its susceptibility to *Aeromonas hydrophila* infection. *Aquaculture*, 530(August 2020), 735828. <https://doi.org/10.1016/j.aquaculture.2020.735828>
- Abdel-Tawwab, M., & Hamed, H.S. (2020). Antagonistic effects of dietary guava (*Psidium guajava*) leaves extract on growth, hemato-biochemical, and immunity response of cypermethrin-intoxicated Nile tilapia, *Oreochromis niloticus*, fingerlings. *Aquaculture*, 529, 735668. <https://doi.org/10.1016/j.aquaculture.2020.735668>
- Adamu, N.M., & Solomon, R.J. (2015). Effect of weight and length on full blood count of catfish (*Clarias gariepinus*). *Report and Opinion*, 7(8), 72-87.
- Adeniyi, O.V., Olaifa, F.E., Emikpe, B.O., & Oyagbemi, A.A. (2018). Experimental Evaluation of the Wound-healing and Antioxidant Activities of Tamarind (*Tamarindus indica*) Pulp and Leaf Meal in the African Catfish (*Clarias gariepinus*). *Acta Veterinaria Eurasia*, 44(2), 63-72. <https://doi.org/10.26650/actavet.2018.011>
- Adeshina, I., Emikpe, B.O., Jenyo-oni, A., Ajani, E.K., & Abubakar, M.I. (2019). Growth performance, gut morphometry and innate immune profiles of common carp, *Cyprinus carpio* juveniles fed diet fortified with *Mitracarpus scaber* leaves extract and its susceptibility to pathogenic bacteria, *Aeromonas hydrophila*. *Acta Biologica*, 5-17. <https://doi.org/10.18276/ab.2019.26-01>
- Adeshina, I., Tiamiyu, L.O., Akpouli, B.U., Jenyo-Oni, A., & Ajani, E.K. (2021). Dietary *Mitracarpus scaber* leaves extract improved growth, antioxidants, non-specific immunity, and resistance of Nile tilapia, *Oreochromis niloticus* to *Gyrodactylus malalai* infestation. *Aquaculture*, 535(December 2020), 736377.

- <https://doi.org/10.1016/j.aquaculture.2021.736377>
- Ajadi, A.A., Jarikre, T., Jibril, A.J., & Emikpe, B. (2022). Protective Evaluation of feed fortified with *Alstonia boonei* and *Mitracarpus scaber* in African Catfish exposed to *Aeromonas hydrophila*: Clinicopathology and immunohistochemistry.
- Ajadi, A.A., Emikpe, B., & Akeem, A. (2021). In vitro Antimicrobial Activities of *Mitracarpus scaber* Against Some Common Bacteria of Aquatic Origin. *Media Kedokteran Hewan*, 8–9. <https://doi.org/10.20473/mkh.v32i3.2021.128-139>
- Ajadi, A., Sabri, M.Y., Atata, J.A., Daodu, O.B., & Emikpe, B.O. (2019). Pathology and immunohistochemical evaluation of *Vibrio alginolyticus* infection in *Macrobrachium rosenbergii*. *Comparative Clinical Pathology*, 28(2), 359–368. <https://doi.org/10.1007/s00580-018-2881-4>
- Ajadi, A., Sabri, M.Y., Dauda, A.B., & Hasliza, A.H. (2018). Growth enhancement and protective potential of feed-based outer membrane proteins against vibriosis in *Macrobrachium rosenbergii*. *Aquaculture International*, February. <https://doi.org/10.1007/s10499-018-0244-4>
- Akinmoladun, A.C., Ibukun, E.O., Afor, E., Akinrinlola, B.L., Onibon, T.R., Akinboboye, A.O., Obuotor, E.M., & Farombi, E.O. (2007). Chemical constituents and antioxidant activity of *Alstonia boonei*. *African Journal of Biotechnology*, 6(10), 1197–1201. <https://doi.org/10.4314/ajb.v6i10.57140>
- Ali, M.N., Ndahi, J.A., Abdullahi, A., & Yelwa, J.M. (2021). Phytochemicals, chemical composition and antioxidants profile of the crude extracts and essential oil of *Mitracarpus scaber* (Goga masu) Phytochemicals, chemical composition and antioxidants profile of the crude extracts and essential oil of *Mitracarpus*. *Journal of Research in Chemistry*, 2(2), 27–31.
- Bell, T.A., & Lightner, D.V. (1988). A handbook of normal penaeid shrimp histology.
- Blaxhall, P.C., & Daisley, K.W. (1973). Routine haematological methods for use with fish blood. *Journal of Fish Biology*, 5(6), 771–781. <https://doi.org/10.1111/j.1095-8649.1973.tb04510.x>
- Chen, J., Liu, N., Zhang, H., Zhao, Y., & Cao, X. (2020). The effects of *Aeromonas hydrophila* infection on oxidative stress, nonspecific immunity, autophagy, and apoptosis in the common carp. *Developmental and Comparative Immunology*, 105(September 2019), 103587. <https://doi.org/10.1016/j.dci.2019.103587>
- Dauda, A.B., Natrah, I., Karim, M., Kamarudin, M.S., & Bichi, A.u.H. (2018). African Catfish Aquaculture in Malaysia and Nigeria: Status, Trends and Prospects. *Fisheries and Aquaculture Journal*, 09(01), 1–5. <https://doi.org/10.4172/2150-3508.1000237>
- Delghandi, M.R., El-Matbouli, M., & Menanteau-Ledouble, S. (2020). *Renibacterium salmoninarum*—the causative agent of bacterial kidney disease in salmonid fish. *Pathogens*, 9(10), 1–19. <https://doi.org/10.3390/pathogens9100845>
- Dytham, C. (2011). *Choosing and using statistics: a biologist's guide*. John Wiley & Sons.
- Ekalu, A. (2021). Medicinal uses, phytochemistry, and pharmacological activities of *Mitracarpus* species (Rubiaceae): A review. *Scientific African*, 11. <https://doi.org/10.1016/j.sciaf.2020.e00692>
- El-Gawad, A., Eman, A., El Asely, A.M., Soror, E.I., Abbass, A.A., & Austin, B. (2020). Effect of dietary *Moringa oleifera* leaf on the immune response and control of *Aeromonas hydrophila* infection in Nile tilapia (*Oreochromis niloticus*) fry. *Aquaculture International*, 28(1), 389–402.
- Ferreira, T., & Rasb, W. (2012). ImageJ user guide: IJ 1.46 r.
- Hal, A.M., & El-barbary, M.I. (2020). Gene expression and histopathological changes of Nile tilapia (*Oreochromis niloticus*) infected with *Aeromonas hydrophila* and *Pseudomonas fluorescens*. *Aquaculture*, 526(August 2019), 735392. <https://doi.org/10.1016/j.aquaculture.2020.735392>
- Han, Z., Zhou, Y., Zhang, X., Yan, J., Xiao, J., Luo, Y., Zheng, H., & Zhong, H. (2020). Ghrelin modulates the immune response and increases resistance to *Aeromonas hydrophila* infection in hybrid tilapia. *Fish and Shellfish Immunology*. <https://doi.org/10.1016/j.fsi.2020.01.006>
- Harikrishnan, R., Rani, M.N., & Balasundaram, C. (2003). Hematological and biochemical parameters in common carp, *Cyprinus carpio*, following herbal treatment for *Aeromonas hydrophila* infection. *Aquaculture*, 221, 41–50. [https://doi.org/10.1016/S0044-8486\(03\)00023-1](https://doi.org/10.1016/S0044-8486(03)00023-1)
- Hossain, S., & Heo, P.G. (2021). Ornamental fish: a potential source of pathogenic and multidrug-resistant motile. *Letters in Applied Microbiology*, 0–3. <https://doi.org/10.1111/lam.13373>
- Ikechukwu, E.S., Onyinye, O.C., Onyebuchi, O.J., & Nzubechukwu, E.V. (2021). Neuroprotective potentials of *alstonia boonei* extracts on biochemical markers of brain integrity in experimental rats. *Tropical Journal of Natural Product Research*, 5(6), 1106–1109. <https://doi.org/10.26538/tjnpr/v5i6.21>
- Junior, G.B. (2021). Fish infections associated with the genus *Aeromonas*: a review of the effects on oxidative status. *Journal of Applied Microbiology*, 1–19. <https://doi.org/10.1111/jam.14986>
- Kwembe, J.T.K., Asumani, M.K., Onautshu, O., Mpiana, P.T., Haesaert, G., & Congo, R.D. (2020). In vitro evaluation of antifungal activity of *Ageratum conyzoides*, *Basella alba* and *Mitracarpus villosus* on the strain of *Lasiodiplodia theobromae* in the Kisangani Region / D R Congo. *BioRxiv*, 1–11.
- Moustafa, E.M., Dawood, M.A.O., Assar, D.H., Omar, A.A., Elbially, Z.I., Farrag, F.A., Shukry, M., & Zayed, M.M. (2020). Modulatory effects of fenugreek seeds powder on the histopathology, oxidative status, and immune related gene expression in Nile tilapia (*Oreochromis niloticus*) infected with *Aeromonas hydrophila*. *Aquaculture*, 515(October 2019), 734589. <https://doi.org/10.1016/j.aquaculture.2019.734589>
- Muhammad Akmal, Aryan Rahimi-Midani, Muhammad Hafeez-ur-Rehman, A.H. and T.-J.C. (2020). Isolation, Characterization, and Application of a Bacteriophage Infecting the Fish Pathogen *Aeromonas hydrophila*. *Pathogens*.
- Nwofor, C., Oyeka, C., Onyenwe, N., & Aqib, F. (2021). Phytochemical analysis and in vitro screening of antifungal activity of *Jatropha multifida*, *Euphorbia hirta* *Occimum gratissimum* and *Mitracarpus scaber* leaves extract. *GSC Biological and Pharmaceutical Sciences*.
- Obiagwu, M.O., Ihekwereme, C.P., Ajaghaku, D.L., & Okoye, F.B.C. (2014). The Useful Medicinal Properties of the Root-Bark Extract of *Alstonia boonei* (Apocynaceae) May Be Connected to Antioxidant Activity. *ISRN Pharmacology*, 2014, 1–4. <https://doi.org/10.1155/2014/741478>
- Ogueke, C.C., Uwaleke, J., Owuamanam, C.I., & Okolue, B. (2014). Antimicrobial activities of *Alstonia boonei* stem

- bark, a Nigerian traditional medicinal plant. *Asian Pacific Journal of Tropical Disease*, 4(S2), S957–S962.
[https://doi.org/10.1016/S2222-1808\(14\)60766-0](https://doi.org/10.1016/S2222-1808(14)60766-0)
- Opoku, F., & Osei, A. (2014). Antimicrobial and Phytochemical Properties of *Alstonia Boonei* Extracts. *Organic Chemistry Current Research*, 4(1), 0–4.
<https://doi.org/10.4172/2161-0401.1000137>
- Owolabi, M.S., Lawal, O.A., Dosoky, N.S., Satyal, P., & William, N. (2013). Chemical composition, antimicrobial, and cytotoxic assessment of *Mitracarpus scaber* Zucc (Rubiaceae) essential oil from southwestern Nigeria. *American Journal of Essential Oils and Natural Products*, 1(1), 4–6.
- Pattanayak, S., Priyadarsini, S., Paul, A., Kumar, P.R., & Sahoo, P.K. (2020). Microbial Pathogenesis Diversity of virulence-associated genes in pathogenic *Aeromonas hydrophila* isolates and their in vivo modulation at varied water temperatures. *Microbial Pathogenesis*, 147(August), 104424.
<https://doi.org/10.1016/j.micpath.2020.104424>
- Schar, D., Klein, E.Y., Laxminarayan, R., Gilbert, M., & Boeckel, T.P. Van. (2020). Global trends in antimicrobial use in aquaculture. *Scientific Reports*, 1–9.
<https://doi.org/10.1038/s41598-020-78849-3>
- Sepperumal, U., & Saminathan, S. (2013). Effect of diethylphthalate on the haematological parameters of the freshwater fish *Oreochromis mossambicus* (Tilapia). *Eur. J. Zool. Res*, 2(4), 55–59.
- Ulas, A., Avci, N., Kos, T., Cubukcu, E., Olmez, O.F., & Degirmenci, M. (2015). Are neutrophil / lymphocyte ratio and platelet / lymphocyte ratio associated with prognosis in patients with HER2- positive early breast cancer receiving adjuvant trastuzumab? *JBUON*, 20(3), 714–722.
- von Danwitz, A., & Schulz, C. (2020). Effects of dietary rapeseed glucosinolates, sinapic acid and phytic acid on feed intake, growth performance and fish health in turbot (*Psetta maxima* L.). *Aquaculture*, 516, 734624.
- Zhang, D., Xu, D.H., Shoemaker, C.A., & Beck, B.H. (2020). The severity of motile *Aeromonas* septicemia caused by virulent *Aeromonas hydrophila* in channel catfish is influenced by nutrients and microbes in water. *Aquaculture*, 519(November 2019), 734898.
<https://doi.org/10.1016/j.aquaculture.2019.734898>