

Effect of Zinc Sulphate (ZnSO₄) on the Gall Bladder of *Clarias batrachus* (Linn. 1758)

Saba Khursheed Khan^{1,*} , Irfan Ashraf Badroo¹ 

¹Dolphin PG Institute of Biomedical and Natural Science Dehradun, Zoology, Uttarakhand, India.

How to cite

Khan, S.K., Badroo, I.A. (2021). Effect of Zinc Sulphate (ZnSO₄) on the Gall Bladder of *Clarias batrachus* (Linn. 1758). *Aquaculture Studies*, 21, 75-81. http://doi.org/10.4194/2618-6381-v21_2_04

Article History

Received 15 September 2020

Accepted 01 February 2021

First Online 08 February 2021

Corresponding Author

Tel.: +919927800047

E-mail: khansaba342@gmail.com

Keywords

Zinc sulphate

Histopathology

C. batrachus

Toxicity

Abstract

Heavy metal exposure to biota has become a severe threat to the environment, as its bioaccumulation, toxicity and persistence is happening at an alarming rate. Heavy metal presence in water bodies has been reported by various researchers. Henceforth their exposure to aquatic organisms is certain. An investigation on the possible toxicological impact of Zinc sulphate on fish *Clarias batrachus* is carried out in laboratory. Histology of gall bladder was used as a marker for evaluation of toxicity after sub lethal exposure. Fish were exposed to sub-lethal concentrations of 5mg/L, 10mg/L and 15mg/L for 20 days. Simultaneous control was also maintained. Principle histological alterations were deformities in the normal structures of columnar epithelial line, muscular layer, and mucosal folds. 15mg/L and 20mg/L exposure of zinc sulphate altered the sub mucosa besides leading the formation of bile crystals, an indication of water loss. The severity of histopathology was exposure dependent. Histopathological alteration in gall bladder can be regarded as sensitive biomarkers of Zinc sulphate toxicological manifestations hence can be utilized for ecotoxicological biomonitoring of aquatic bodies.

Introduction

Our habitats are being depreciated day by day due to increased environmental pollution by means of various anthropogenic activities. The industrial sewage that contain toxic substances like heavy metals, pesticides and other chemicals are discharged into the water bodies. Unrestrained release of heavy metals into the environment through discharge of industrial effluents, sewage and agro-chemicals into the water resources constitutes a potential threat to natural ecosystems because of their toxicity, persistence and tendency to bio-accumulate in food chains (Jan, A.T., Azam, M *et al.*, 2015). It also tends to change the internal dynamics of the aquatic ecosystem into irreversible and inflexible condition leading to severe damage and even death of aquatic fauna including fish (Panigrahi, A. 2014). Zinc is one of the most common elements in the earth's crust. It is commercially one of

the most widely used metals in the world (Emoyan, O. O., Ogban, F.E., and Akarah, E. 2006). Heavy metal contamination of aquatic ecosystem has long been recognized as a serious problem and may have lethal effect on ecological balance of recipient environment and diversity of aquatic organism (Charjan, 1997; Farombi *et al.*, 2007). Presence of heavy metals have been reported in the water and are further added into water bodies as a result of direct input of atmospheric deposition, leaching of mineral and soil erosion due to rainwater which causes the hazardous effects on aquatic biota particularly fishes (Mulley *et al.*, 1996). When fishes are exposed to elevated level of heavy metals, they tend to take these metals up from their direct environment (Hoo *et al.*, 2004). Once these toxic substances enter body, they damage and alter the fish physiology (Arasta *et al.*, 1999; Begum, 2004) and finally accumulates in various body tissues. In this context, one of the most heavy metal contaminant, Zinc sulphate was

taken in account and its toxicity was studied at histological level. Zinc sulphate has an important role in cellular metabolism acting as co-factors for number of important enzymes. However, it can become toxic when elevated level is found in the environment (Marr *et al.*, 1996; Karan *et al.*, 1998). Zinc sulphate has an important role in cellular metabolism acting as co-factors for number of important enzymes. However, it can become toxic when elevated level is found in the environment (Plum, L. M., Rink, L., & Haase, H. 2010). Studies on the toxicity of metals on fish have been focused at short-term exposure, rather than investigating the toxic impact at long-term exposure. Under conditions of acute, high-dose metal exposure, the maintenance of branchial osmoregulation and gas exchange is of prime importance for the survival of the fish; whereas under conditions of sublethal, chronic metal intoxication, the adaptive capacity of internal metal accumulating organs such as the liver may gain importance (McDonald and Wood, 1993; Schlenk *et al.*, 1999; Stubblefield *et al.*, 1999). Bioaccumulation of metals reflects the amount ingested by the organism, the way in which the metals are distributed among the different tissues and extent to which metal is retained in each tissue type. Accumulation of zinc has attained a serious dimension causing a pathogenic stage like Alzheimer's disease. Zn in certain concentrations is desirable for the growth of freshwater fish's but it's over accumulation is hazardous to exposed organisms as well as to those who consume directly or indirectly through food chains.

Fishes are very sensitive to any change in their environment and play significant role in assessing the contaminant water bodies (Lakra and Nagpure, 2009; Badroo *et al.*, 2019). The test organism used for the present study is one of the most edible fish *C. batrachus* in India. Heavy metals besides contaminating the aquatic life have an indirect effect on humans, as fish constitutes a valuable commodity of human consumption. Eco-friendly environment is a necessary condition for the wellbeing of human race. The degree of contamination in aquatic environment is frequently assessed by comparing containment concentration in associated biota. Since bioconcentration of compounds have been determined in the environment, it has been observed that there are many quantitative relationships between structure and biological activity of chemicals established in aquatic system Thus, became a serious concern from human health point of view. However, the main sites of these heavy metal uptake and accumulation are the gills and gastrointestinal tracts.

The aim of present study is to figure out histopathological changes in gallbladder of *C. batrachus* after sub lethal exposure to Zinc sulphate. Study of histological alteration may prove helpful in establishing water quality guidelines (Mc Bride and M. B. 1995) besides knowing the histopathological response at sublethal dose. Any peculiar type of alteration of cells may indicate the presence of disease or the effect of toxic substance.

Material and Methods

Experimental Fish Specimen

C. batrachus was selected as model organism in this study, because it has well documented general biology, short developmental time, easy culturing and year around reproduction. It is a hardy fish and can stand with the aquarium condition very well, because of these characteristics *C. batrachus* is consider suitable for toxicity test.

Collection, Transport and Acclimatization

Samples of live *C. batrachus* were brought from market (Machi Bazaar Ghanta Ghar, Dehradun), (latitude and longitude coordinates are: 30.316496,78.032188) India. The sample fish were immediately brought to the laboratory in well aerated containers, to avoid hyperactivity, physical injuries and stress to the fish. The fish were transferred to glass aquaria (30 L capacity of water) individually and acclimatized for one week in static system as suggested by Mohapatra, (1989,1995).

Exposure

The acclimated fish were divided into four groups. One control and three tests, each test was treated with different concentration of Zinc sulphate (5 mg/L, 10 mg/L and 15 mg/L) respectively as reported by Srivastava and Prakash (2018). In 4th aquaria Zinc sulphate was not added, and this was kept as controlled setup. The fish were kept under observation for 20 days in Zinc sulphate containing water. The effects of Zinc concentrations on histology of gall bladder were investigated after 20 days. During the exposure morphological and behavioral changes were also monitored as suggested by (Saxena, M. P., & Saxena, H. 2008)

Histopathological Studies

The fish was killed by decapitation and the gallbladder was removed. The gallbladder was first washed with tap water and cut into small pieces. Before cutting down into pieces the gall bladder was washed in buffer phosphate. Preserved tissue was carefully removed and was fixed by Immersion in Bouin's solution for 24 hours and dehydrated in graded series of alcohol. Each Sample was run through the 6 grades of alcohol separately, each for 1 hour, in increasing order from 30% to 100%. Two changes of Xylene of 1 hour each were followed by cold impregnation and hot impregnation (2 changes) of 20 minutes each. After complete fixation to support the tissue during sectioning process the tissue was processed, sectioned, and stained by following standard histological technique of dehydration, clearing and embedding in paraffin wax (melting point between

58-60°C) and after that block making was done, serial thin sections or slices of 4-5 μm were cut using the microtome. Standard procedure was followed as per (Humason, 1972). Stained with hematoxylin and counter stained with eosin, cleared in xylene and mounted in Digital Picture Exchange (DPX).

Microscopy

The slides were observed under Compound microscope and compared with the slides from control group for the determination of histological alterations of the gallbladder.

Results and Discussion

Heavy metals are known for their strong action on biological tissues. Metal ions once absorbed into body are capable of reacting with a variety of active binding sites and thus can disturb the normal physiology of an organism. In the present study, an attempt was made to examine the sub-lethal toxic effect of zinc sulphate on the gallbladder of *C. batrachus*. Changes in the fish often reflect alteration of physiological and histopathological state of fish after exposure to different concentration of zinc sulphate. Gallbladder is a pear-shaped sac like structure for bile storage. It is made up of mucosa, submucosa and muscularis layer. Histology of control gallbladder showed normally differentiated muscular layer (M), submucosa (SM), muscular folds (MF) and epithelium (E) (Figure 1). Sub lethal exposure of Zinc sulphate (5 mg/L) altered the normal structures of epithelial line, muscular layer and mucosal folds, besides altering the columnar epithelial cells (Figure 2). Histological alterations were evident after exposure to concentration (10mg/L) of Zinc sulphate. Principle

alterations made were rupturing of mucosal folds and formation of crystals of bile in the lumen of the gall bladder (Figure 3). In case of 15mg/L, alteration in the tissue was severe mainly marked with rupturing of submucosa and crystallization of bile salts (Figure 4). Sub lethal exposure to Zinc sulphate induced tissue alteration becomes severe with increasing exposure period and was dose dependent.

Among heavy metals, zinc is used in various forms which eventually find its way into the river or sea. Although, small quantities of zinc are required for the normal development and metabolism (Srivastava and Sharma, 1996; Srivastava and Kaushik, 2001; Shukla *et al.*, 2002), but if its level exceeds the Physiological requirements, it can act as a toxicant. Accumulation of zinc in various organs of fish has been described by Gupta and Sharma (1994), Pandey *et al.*, (1995) and Singh and Gaur, (1997). Chronic exposure of Zinc, to fish has been shown to cause a variety of histopathological, behavioral, biochemical and physiological changes including loss of appetite, reduced growth, decreased aerobic scope and mortality (Mc Geer *et al.*, 2000; Sloman *et al.*, 2003). Histopathological investigations are a sensitive tool to detect direct effects of xenobiotics and toxic chemicals within target organs of fish (Schwaiger *et al.*, 1997).

Zinc is essential for proper functioning of the body and a necessary trace element that contributes to the structure of more than 300 proteins which play a role in the growth, reproduction, development and immune system catalysts in fish (Chanda, S., Paul, B. N. *et al.*, 2015). It is used in various industrial operation forms and excessive zinc finds its way into 150 reservoirs, lakes and rivers. The source of zinc like other heavy metals in natural waters is from geological rock weathering or from anthropogenic activities such as industrial and

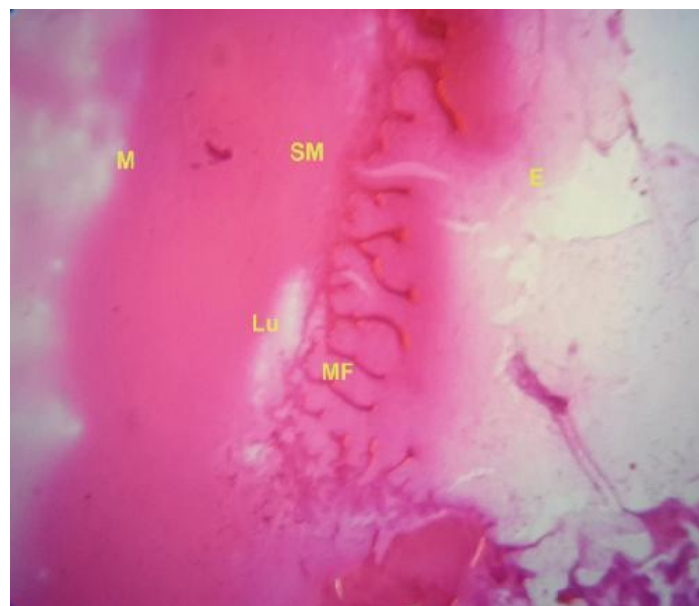


Figure 1. Slide of Gall Bladder of Control Fish Showing Normal histology (10X10) (M: Muscular Layer, SM: Sub Mucosa, E: Epithelium, Lu: Lumen & MF: Mucosal Folds)

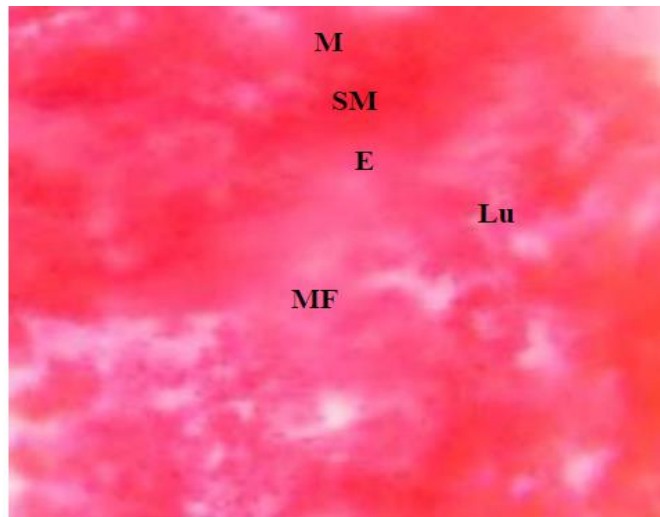


Figure 2. Slide of Gall Bladder of fish of 5mg/L of ZnSO₄ Concentration Showing Loosing of Muscular Layer and Rupturing of Mucosal Folds (M: Muscular Layer, SM: Sub Mucosa, E: Epithelium, Lu: Lumen & MF: Mucosal Folds)

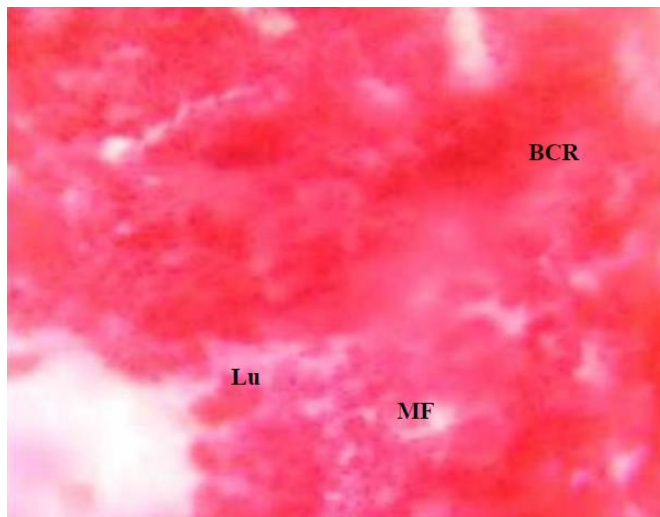


Figure 3. Slide of Gall Bladder of fish of 10mg/L of ZnSO₄ Concentration showing Loosing and Rupturing of Mucosal Folds (Lu: Lumen & MF: Mucosal Folds) and some Bile Crystals (BCR)

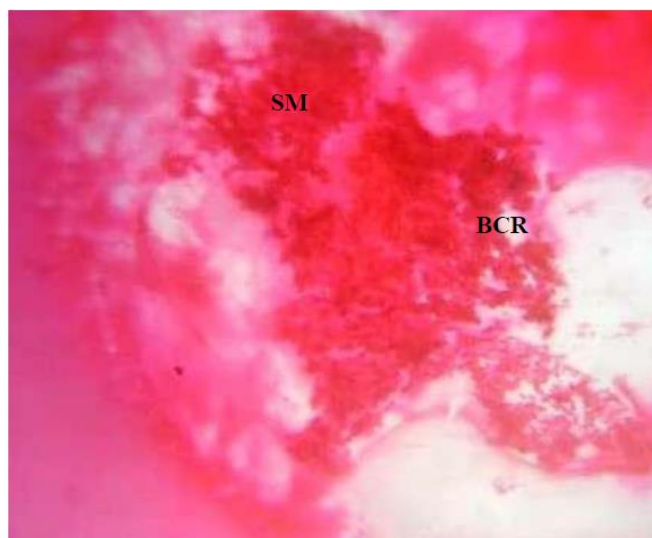


Figure 4. Slide of Fish at 15 mg/L of ZnSO₄ Concentration Showing rupturing of Submucosa & Bile Crystals Due to Loss of Water (10X10) (SM: Submucosa & BCR: Bile Crystals)

domestic waste water discharge (Bradl, H. B. (2005). However, it occurs widely in nature as sulphide, carbonate and hydrated silicate ores, and frequently accompanied by other metals like iron and cadmium (Afshan, S., Ali, S., Ameen, U.S. *et al.*, 2014). It is ubiquitous aquatic pollutant.

Studies on the freshwater fish, *C. batrachus* when exposed to zinc sulphate concentration shows behavioral changes with histopathological alternations. Control fish gall bladder shows normal structure and test fish show anomaly in their histology. The histological alterations were duration-dose dependent. In the present study gallbladder showed the deformities in the normal structures of epithelial line, muscular layer, and mucosal folds. Columnar epithelial cells get destroyed at many places due to zinc intoxication. In the same way mucosal folds got destroyed and deformities in the muscular layer appear due to destruction of smooth muscle cells. Alterations in the main layers of gallbladder were prominent affecting its vital function. The alteration as discussed previously were in tune with Katti and Sathynesen, (1984) in *C. batrachus*. They also reported that Zn exposure lowered lipid content. Corroborating results were found by (Nakagawa *et al.*, 1979; Waku *et al.*, 1980; Rana *et al.*, 1980 & 1981). Rathore and Naik, (1994) investigated the effect of Cadmium on gallbladder and found that it might have lowered lipid metabolism hence less bile was utilized, and good amount was accumulated which resulted in swollen gall bladder. Sublethal exposure of high dose of Zinc sulphate (10mg/L and 15 mg/L) lead the crystallization of bile in the lumen of the gall bladder. This may be due to excess loss of water. It also shows rupturing of submucosa. These alterations are in tune with the results of Tripathi *et al.*, (2012). They reported high concentration of Zinc causes formation of bile crystals due to loss of water and in low concentration it shows anomaly in normal histology. The results apparent from the Figure 4 showed resemblance with the reports found by (Montaser, M., *et al.*, 2010; Besirovic, H., *et al.*, 2010). In the same way present study is in agreement with the Bhoraskar and Kothari (1997), Wong *et al.*, (1997); Kumar and Pant, (1981). Osman *et al.*, (2009) recorded congestion and hemorrhage in the hepatic sinusoids with dilation of hepatic vessels, vacuolization and degeneration of hepatic cells with fatty changes with atrophy of pancreatic acini in liver of the *Oreochromis niloticus* exposed to the polluted water containing heavy metal salts. Moreover, it was also reported by several studies that chronic heavy metal accumulation in the liver of fish causes hepatocyte lysis, cirrhosis and ultimately death (Rajkowska, M., & Protasowicki, M. (2013); Varanka *et al.*, 2001; Saxena, M. P., and Saxena, H. 2008). To check the continual introduction of these heavy metals into the food chain, a more cautious application of insecticides and pesticides should be employed and effluents from industries must be treated before disposal.

Conclusion

Exposure to sublethal concentration of Zinc sulphate caused dose-duration dependent histopathological alterations. The alterations or lesions made in gallbladder might result in the dysfunction of important functions. Histological condition of fishes is affected to large extent which is a sign of toxicity. Thus, it can be concluded that Zinc sulphate is hazardous to the aquatic organisms particularly to fishes. Post-mortem artefacts are one of the limitations of histological study hence other studies needs to be carried out for greater significance.

Ethical Statement

The research was permitted by ethical committee of college.

Funding Information

There was no funding.

Author Contribution

I Saba Khursheed khan certify that I have conceptualized and designed this work. The analysis of the data as well as methodology, software, validation, investigation, resource, data curation, writing original draft, term, supervision, visualization, project administration was done by me.

Ifnan Ahmad Badroo helped in writing & editing.

Conflict of Interest

The authors declare that they have no conflict of interest.

Acknowledgments

Authors are thankful to the Department of Zoology of Dolphin (Pg) Institute of Biomedical and Natural Sciences, for their support in carrying out the research successfully.

References

- Arasta, T., Bais, V. S., & Thakur, P. B. (1999). Changes in selected biochemical parameters in the liver and muscles of fish *Mystus vittatus* exposed to aldrin. *Environment Pollution Management*, (Ed.V.S. Bais) *Creative Pub., Sagar PP*, 109-112.
- Afshan, S., Ali, S., Ameen, U.S., Farid, M., Bharwana, S.A., Hannan, F., & Ahmad, R. (2014). Effect of different heavy metal pollution on fish. *Research journal of chemical and environmental sciences*, 2(1), 74-79.
- Badroo, I.A., Wani, K.A., Nandurkar, H.P., & Khanday, A.H. (2019). Renewal Acute Toxicity of Broad-Spectrum Herbicide, Paraquat Dichloride in *Channa punctatus* (Bloch). *Environmental Claims Journal*, 31(4), 289-303.

- <https://doi.org/10.1080/10406026.2019.1609796>
- Begum, G. (2004). Carbofuran insecticide induced biochemical alterations in liver and muscle tissues of the fish *Clarias batrachus* (linn) and recovery response. *Aquatic toxicology*, 66(1), 83-92.
<https://doi.org/10.1016/j.aquatox.2003.08.002>
- Bhoraskar, S., & Kothari, S. (1997). Toxicity of mercury and zinc in the liver of a cat fish *Clarias batrachus*. *Recent Advances in fresh water Biology*. Rao, Amol Publication Pvt. Ltd.
- Besirovic, H., Alić, A., Prasovic, S., & Drommer, W. (2010). Histopathological effects of chronic exposure to cadmium and zinc on kidneys and gills of brown trout (*Salmo trutta m. fario*). *Turkish Journal of Fisheries and Aquatic Sciences*, 10(2), 255-262.
- Bradl, H.B. (2005). Sources and origins of heavy metals. In *Interface science and technology* (Vol. 6, pp. 1-27). Elsevier.
- Chargan, A.P. (1997). Studies on enzymes profiles and kinetics of the Fish *Channa Orientalis* SCH.
- Chanda, S. Paul, B.N. Ghosh, K. & Giri, S.S. (2015). Dietary essentiality of trace minerals in aquaculture-A Review. *Agricultural Reviews*, 36(2), 100-112.
- Emoyan, O.O., Ogban, F.E., & Akarah, E. (2006). Evaluation of heavy metals loading of River Ijana in Ekpan Warri, Nigeria. *Journal of Applied Sciences and Environmental Management*, 10(2).
- Farombi, E.O., Adelowo, O.A., & Ajimoko, Y.R (2007). Biomarkers of oxidative stress and heavy metal levels as indicators of environmental pollution in African cat fish (*Clarias gariepinus*) from Nigeria Ogun River. *International journal of Environmental research and Public health*, 4(2), 158-165.
<https://doi.org/10.3390/ijerph2007040011>
- Gupta, A.K., & Sharma, S.K. (1994). Bioaccumulation of zinc in *Cirrhinus mrigala* (Hamilton) fingerlings during short-term static bioassay. *Journal of Environmental Biology*, 15(3), 231-237.
- Humason, G.L. (1972). Specific staining methods. *Animal tissue techniques*. WH Freeman and Co., San Francisco, CA, 183-185.
- Hoo, L.S., Sampat, A., & Othman, R.M. (2004). The level of selected heavy metals (Cd, Cu, Fe, Pb, Mn and Zn) at residential area nearby Labu river system riverbank, Malaysia. *Research Journal of Chemistry and Environment*, 8(3), 24-29.
- Jan, A.T., Azam, M., Siddiqui, K., Ali, A., Choi, I., & Haq, Q.M. (2015). Heavy metals and human health: mechanistic insight into toxicity and counter defense system of antioxidants. *International journal of molecular sciences*, 16(12), 29592-29630.
- Kumar, S., & Pant, S.C. (1981). Histopathologic effects of acutely toxic levels of copper & zinc on gills, liver & kidney of *Puntius conchonius* (Ham.). *Indian journal of experimental biology*, 19(2), 191-194.
- Karan, V., Vitorović, S., Tutundžić, V., & Poleksić, V. (1998). Functional enzymes activity and gill histology of carp after copper sulfate exposure and recovery. *Ecotoxicology and Environmental Safety*, 40(1-2), 49-55.
<https://doi.org/10.1006/eesa.1998.1641>
- Katti, S.R., & Sathyanesan, A.G. (1984). Changes in tissue lipid and cholesterol content in the catfish *Clarias batrachus* (L.) exposed to cadmium chloride. *Bulletin of environmental contamination and toxicology*, 32(4), 486-490. <https://doi.org/10.1007/BF01607526>
- Lakra, W.S., & Nagpure, N.S. (2009). Geno toxicological studies in fishes: a review. *Indian Journal of Animal Sciences*, 79(1), 93-97.
- Marr, J.C.A., Lipton, J., Cabela, D., Hansen, J.A., Bergman, H.L., Meyer, J.S., & Hogstrand, C. (1996). Relationship between copper exposure duration, tissue copper concentration, and rainbow trout growth. *Aquatic Toxicology*, 36(1-2), 17-30.
[https://doi.org/10.1016/S0166-445X\(96\)00801-6](https://doi.org/10.1016/S0166-445X(96)00801-6)
- McDonald, D.G., & Wood, C.M. (1993). Branchial mechanisms of acclimation to metals in freshwater fish. In *Fish ecophysiology* (pp. 297-321). Springer, Dordrecht.
- McGeer, J.C., Szebedinszky, C., McDonald, D.G., & Wood, C.M. (2000). Effects of chronic sublethal exposure to waterborne Cu, Cd or Zn in rainbow trout. 1: Iono regulatory disturbance and metabolic costs. *Aquatic Toxicology*, 50(3), 231-243.
[https://doi.org/10.1016/S0166-445X\(99\)00105-8](https://doi.org/10.1016/S0166-445X(99)00105-8)
- Muley, D.V., Kamble, G.B., & Gaikwad, P.T. (1996). Endo sulfan toxicity in the freshwater fish *Tilapia mossambica*. *Journal of Aquatic Biology*, 11, 61-66.
- Montaser, M., Mahfouz, M.E., El-Shazly, S.A., Abdel-Rahman, G.H., & Bakry, S. (2010). Toxicity of heavy metals on fish at Jeddah coast KSA: Metallothionein expression as a biomarker and histopathological study on liver and gills. *World Journal. Fish Marial. Science*, 2(3), 174-185.
- McBride, M.B. (1995). Toxic metal accumulation from agricultural use of sludge: are US Environment Protection Agency regulations protective? *Journal of Environmental Quality*, 24(1), 5-18.
<https://doi.org/10.2134/jeq1995.00472425002400010002x>
- Mohapatra, B.C. (1995). *Effects of some heavy metals copper, zinc and lead on certain tissues of Liza parsia (Hamilton and Buchanan) in different environments* (Doctoral dissertation, Central Marine Fisheries Research Institute. Submitted to Cochin University of Science and Technology).
- Mohapatra, B.C. (1989). *Effect of " Nuvan" on some biochemical and physiological parameters of Liza parsia (Hamilton and Buchanan)* (Doctoral dissertation, Cochin University of Science and Technology).
- Nakagawa, M., Takamura, M., & Kojima, S. (1979). Some heavy metals affecting the lecithin-cholesterol acyl transferase reaction in human plasma. *The Journal of Biochemistry*, 81(4), 1011-1016.
<https://doi.org/10.1093/oxfordjournals.jbchem.a131522>
- Osman, M.M., El-Fiky, S.A., Soheir, Y.M., & Abeer, A.I. (2009). Impact of water pollution on histopathological and electrophoretic characters of *Oreochromis niloticus* fish. *Reserch Journal Environment Toxicol*, 3(1), 9-23.
<http://dx.doi.org/10.3923/rjet.2009.9.23>
- Pandey, B.K., Sarkar, U.K., Bhowmik, M.L., & Tripathi, S.D. (1995). Accumulation of heavy metals in soil, water, aquatic weed and fish samples of sewage-fed ponds. *Journal of Environmental Biology*, 16(2), 97-103.
- Plum, L.M., Rink, L., & Haase, H. (2010). The essential toxin: impact of zinc on human health. *International journal of environmental research and public health*, 7(4), 1342-1365.
- Panigrahi, A. (2014). Heavy metal toxicity. In *Everyman's Science (Indian Science Congress)* (Vol. 68, No. 6, p. 418).
- Rana, S.V.S., Kumar, A., Bhardwaj, N.G., & Kumar, A. (1980). Lipids in the liver and kidney of rats, fed various heavy metals. *Cells Tissues Organs*, 108(3), 402-412.

- <https://doi.org/10.1159/000145323>
- Rana, S.V., Agrawal, V.P., & Hardway, N.G.B. (1981). The effect of dietary cadmium and zinc on lipids, proteins and carbohydrates in rats. *Arhiv za higijenu radai toksikologiju*, 32(2), 157-161.
- Rathore, H.S., & Naik, B.K. (1994). Protection of fish liver with live 52 against cadmium intoxication-A histological study. *Biologia-Lahore*, 40,1-4.
http://www.liversupport.co.uk/Research/Radiation_Ch_emothrapy/liv109.pdf
- Rajkowska, M., & Protasowicki, M. (2013). Distribution of metals (Fe, Mn, Zn, Cu) in fish tissues in two lakes of different trophy in Northwestern Poland. *Environmental monitoring and assessment*, 185(4), 3493-3502.
- Saxena, M.P., & Saxena, H. (2008). Histopathological changes in lymphoid organs of fish after exposure to water polluted with heavy metals. *International Journal Vet. Med*, 5, 315 1-3
- Schwaiger, J., Wanke, R., Adam, S., Pawert, M., Honnen, W., & Triebskorn, R. (1997). The use of histopathological indicators to evaluate contaminant-related stress in fish. *Journal of Aquatic Ecosystem Stress and Recovery*, 6(1), 75-86.
- Srivastava N.K. and Prakash S. Morphological, behavioural and haematological alterations in Catfish, *Clarias batrachus* (Linn.) after acute Zinc Toxicity. *International journal on Biological Sciences*. 2018;9(1):78-84.
- Sloman, K.A., Baker, D.W., Ho, C.G., McDonald, D.G., & Wood, C.M. (2003). The effects of trace metal exposure on agonistic encounters in juvenile rainbow trout, *Oncorhynchus mykiss*. *Aquatic toxicology*, 63(2), 187-196.
[https://doi.org/10.1016/S0166-445X\(02\)00176-5](https://doi.org/10.1016/S0166-445X(02)00176-5)
- Schlenk, D., Davis, K.B., & Griffin, B.R. (1999). Relationship between expression of hepatic metallothionein and sublethal stress in channel catfish following acute exposure to copper sulphate. *Aquaculture*, 177(1-4), 367-379. <https://www.elibrary.ru/item.asp?id=136191>
- Stubblefield, W.A., Steadman, B.L., La Point, T.W., & Bergman, H.L. (1999). Acclimation-induced changes in the toxicity of zinc and cadmium to rainbow trout. *Environmental Toxicology and Chemistry: An International Journal*, 18(12), 2875-2881.
<https://doi.org/10.1002/etc.5620181231>
- Srivastava, N., & Sharma, R. (1996). Toxicity of Zinc in Fish (*Channa Punctatus* Bloch) As Influenced by Temperature and pH of Water. *Indian Journal of Animal Nutrition*, 13(2), 87-90.
- Srivastava, N., & Kaushik, N. (2001, December). Use of fish as bioindicator of aquatic pollution. In *Proceedings of the International Congress of Chemistry and Environment* (pp. 227-229).
- Shukla, V., Rathi, P., & Sastry, K.V. (2002). Effect of cadmium individually and in combination with other metals on the nutritive value of fresh water fish, *Channa punctatus*. *Journal of environmental biology*, 23(2), 105-110.
- Singh, M., & Gaur, K.K. (1997). Effects of mercury, zinc and cadmium on the proteinic value and their accumulation in trunk muscle of *Channa punctatus* (Bloch.). *Advances Bios*, 16(11), 109-114.
- Tripathi, M., Mishra, R.P., & Girdoniya, V. (2012). Histopathological changes in gallbladder of a teleost fish *Catla catla* treated with 1.2% lindane. *Journal of Fisheries and Aquaculture*, 3(2), 44-46.
- Varanka, Z., Rojik, I., Varanka, I., Nemcsók, J., & Abraham, M. (2001). Biochemical and morphological changes in carp (*Cyprinus carpio* L.) liver following exposure to copper sulfate and tannic acid. *Comparative Biochemistry and Physiology Part C: Toxicology & Pharmacology*, 128(3), 467-477.
- Waku, K., Hayakawa, F., & Nakazawa, Y. (1980). The effect of cadmium ions and cadmium metallothionein on the activities of phospholipid-synthesizing enzymes of rat liver microsomes in vitro. *Archives of biochemistry and biophysics*, 204(1), 288-293.
<https://doi.org/10.1289/ehp.845437>
- Wong, M.H., Luk, K.C., & Choi, K.Y. (1977). The effects of zinc and copper salts on *Cyprinus carpio* and *Cteno pharyngo donidellus*. *Cells Tissues Organs*, 99(4), 450-454.
<https://doi.org/10.1159/000144869>